



ThinPrep® Non-Gyn Lecture Series

Urinary Cytology

Benefits of ThinPrep® Technology

The use of ThinPrep Non-Gyn for specimens from the urinary tract:

- Optimizes cell preservation
- Standardizes specimen preparation
- Simplifies slide screening
- Offers the versatility to perform ancillary testing



Materials

- ThinPrep® 2000 Processor or ThinPrep 5000 Processor
- ThinPrep Microscope Slides
- ThinPrep Non-Gyn Filters (Blue)
- Multi-Mix™ Racked Vortex
- CytoLyt® and PreservCyt® Solutions
- Optional - UroCyte® Urine Collection Kit



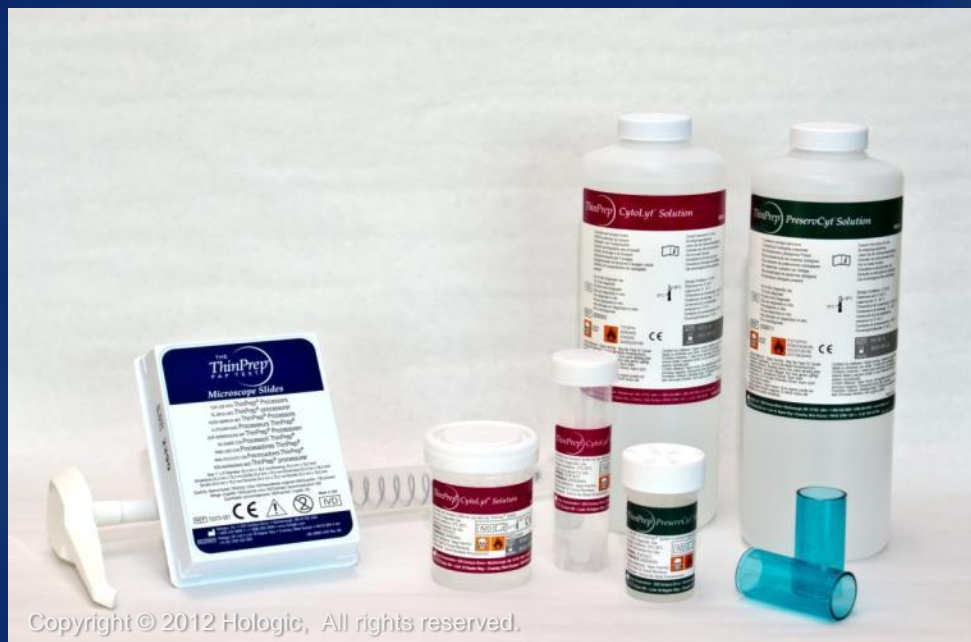Materials

- 50 ml capacity “swing arm” centrifuge
- 50 ml centrifuge tubes
- Slide staining system and reagents
- 1 ml plastic transfer pipettes
- 95% alcohol
- Coverslips and mounting media
- Optional - Glacial Acetic Acid and saline for troubleshooting



Hologic® Solutions

- CytoLyt®
- PreservCyt®



Copyright © 2012 Hologic, All rights reserved.

Hologic® Solutions

Cytolyt® Solution

- Methanol-based, buffered preservative solution
- Lyses red blood cells
- Prevents protein precipitation
- Dissolves mucus
- Preserves morphology for 8 days at room temperature
- Intended as transport medium
- Used in specimen preparation prior to processing



Hologic® Solutions

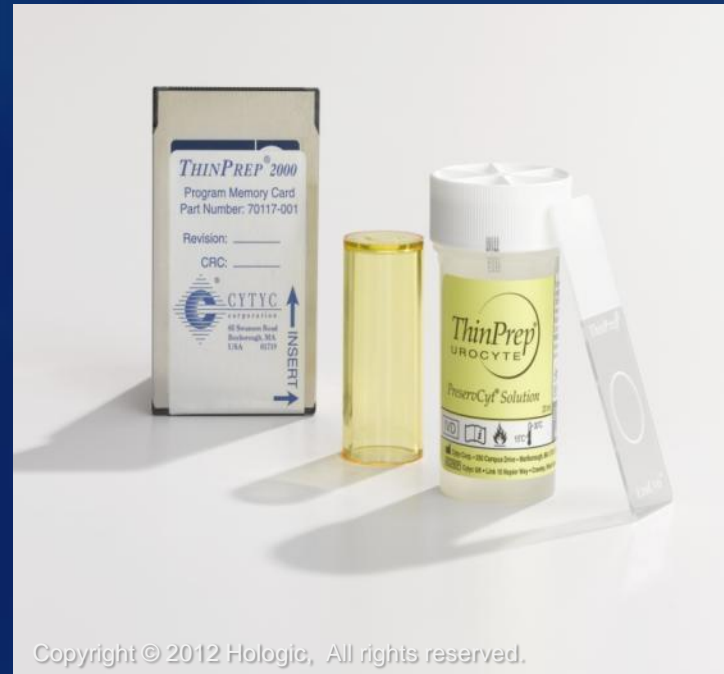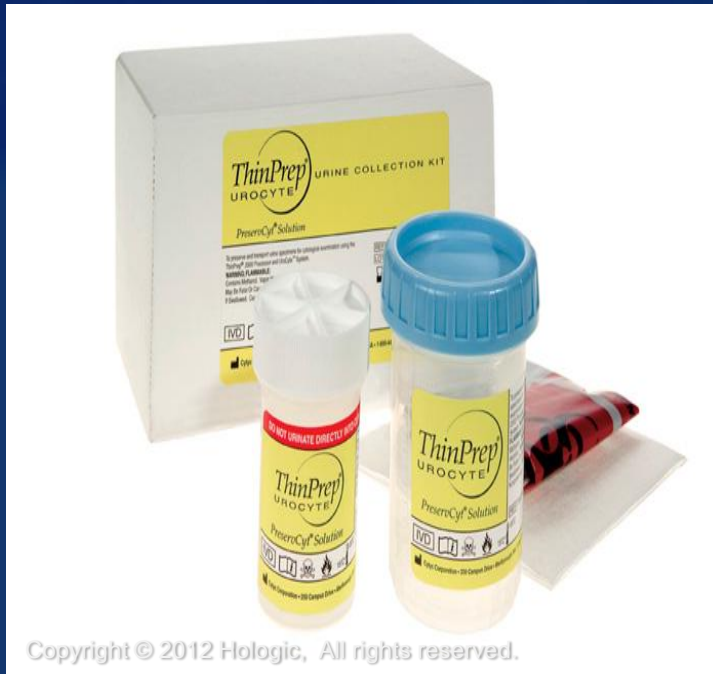PreservCyt® Solution

- Methanol-based, buffered solution designed to support cells during transport and processing
- Specimens must be stored in PreservCyt Solution prior to processing
- PreservCyt Solution cannot be substituted with any other reagents
- Cells in PreservCyt Solution are preserved for up to **3 weeks** in a temperature range of 4 -37 C



Hologic® Supplies


UroCyte® Collection Kit, Filters and Slides



Hologic® Supplies

UroCyte® Filters and Slides

- ThinPrep® 2000 compatible with software card
- ThinPrep 5000 run on Sequence UroCyte
- Specialized filter: 10 mm diameter filter area, 8.5micron pore size
- Specialized microscope slides
- 16 mm diameter ring for easy cell spot location



UroCyte Filter

Relocation ring

Cell deposition area



Sample Collection

- For Routine Urine Cytology prep:
 - Fresh – recommended
 - CytoLyt®
 - If fresh collection is not possible, collect samples directly into CytoLyt Solution
 - The minimum CytoLyt to sample ratio should be 1:3 and is not considered a wash step, but only a collection step
 - PreservCyt®
 - Fresh urine can be mixed with a 2:1 urine-to-PreservCyt Solution ratio



Sample Collection

- For UroVysion™ prep:
 - ThinPrep® UroCyte® Urine collection kit – recommended
 - PreservCyt®
 - Fresh urine can be mixed with a 2:1 urine-to-PreservCyt Solution ratio

Note - If using the UroCyte Urine Collection Kit, do not exceed a 2:1 ratio of urine to PreservCyt Solution. If the urine volume exceeds 60ml, pour off excess. A minimum volume of 33ml of urine is required to perform the UroVysion assay.



Sample Preparation Overview

Routine Urine Cytology

1. Sample collection
2. Concentrate by centrifugation
3. Pour off supernatant and vortex
4. Add 30mls of CytoLyt[®] Solution. Repeat centrifugation, pour off supernatant.
5. Evaluate cell pellet. If cell pellet is not free of blood, do a second CytoLyt wash
6. Add recommended # of drops of specimen to PreservCyt[®] Solution Vial
7. Allow to stand for 15 minutes
8. Prepare slide on ThinPrep[®] 2000 using Sequence 2 or ThinPrep 5000 using Sequence Non-Gyn
9. Fix, Stain, and Evaluate



Sample Preparation Overview

Urovision™

1. Sample collection
2. Transfer sample evenly into two 50ml centrifuge tubes
3. Concentrate by centrifugation. Pour off supernatant and vortex
4. Add 30mls of CytoLyt® Solution. Repeat centrifugation, pour off supernatant
5. Add 30mls of CytoLyt to one 50ml tube, vortex. Add contents to second 50ml tube, vortex. Repeat centrifugation, pour off supernatant.
6. Evaluate cell pellet. If pellet is not free of blood, do a CytoLyt wash
7. Add recommended # of drops of specimen to PreservCyt® Solution Vial and allow to stand for 15 minutes
8. Prepare slide on ThinPrep® 2000 using Sequence 5 or ThinPrep 5000 using Sequence UroCyte®
9. Fix, stain, and evaluate for cytology OR perform molecular testing according to manufacturer's instructions for use



Sample Preparation Techniques

- Centrifugation 600g for 10 minutes or 1200g for 5 minutes
 - Concentrate cellular material in order to separate the cellular components from the supernatant



Refer to Centrifuge Speed Chart in the ThinPrep[®] 2000 or ThinPrep 5000 Owners Manual, Non-Gynecologic section to determine the correct speed for your centrifuge to obtain force of 600g or 1200g

Sample Preparation Techniques

- Pour off supernatant
 - Invert the centrifuge tube 180° in *one smooth movement*, pour off all supernatant and return tube to its original position

(Note: Failure to completely pour off the supernatant may result in a sparsely cellular sample due to dilution of the cell pellet).



Sample Preparation Techniques

- Vortex to re-suspend cell pellet
 - Purpose of this step is to randomize the cell pellet and to improve the results of the subsequent CytoLyt[®] solution washing procedure
 - Place the centrifuge tube onto a vortexor and agitate the cell pellet for 3 seconds or vortex manually by syringing the pellet back and forth with a plastic pipette



Sample Preparation Techniques

- CytoLyt[®] Solution Wash
 - Preserve cellular morphology while lysing red blood cells, dissolving mucus and reducing protein precipitation
 - Add 30 ml of CytoLyt Solution to a cell pellet, concentrate by centrifugation, pour off the supernatant, vortex and evaluate cell pellet



Sample Preparation Techniques

- Evaluate cell pellet

If cell pellet is white, pale pink, tan or not visible.

Calculate number of drops of specimen to be added to the PreservCyt[®] Solution Vial
(will be discussed in detail on future slides)

If cell pellet is distinctly red or brown indicating the presence of remaining blood conduct a second CytoLyt[®] Wash



Sample Preparation Techniques

- Calculate how many drops of specimen to add to PreservCyt[®] vial:
 - If pellet volume is $> 1\text{ml}$ (*if not consider next 2 slides*)
 - Add 1ml of CytoLyt[®] Solution into the tube and vortex briefly to resuspend the cell pellet
 - Transfer 1 drop of the specimen to a fresh PreservCyt Solution Vial



Sample Preparation Techniques

- Calculate how many drops of specimen to add to PreservCyt[®] vial:
 - If pellet is clearly visible and pellet volume is $< 1\text{ml}$ *(if not consider next slide)*
 - Vortex pellet and transfer 2 drops to a fresh PreservCyt solution vial



Sample Preparation Techniques

- Calculate how many drops of specimen to add to PreservCyt[®] vial:
 - If pellet is not visible or scant
 - Add contents of a fresh PreservCyt Solution Vial into the tube and vortex briefly to mix the solution
 - Pour entire sample back into the vial



Troubleshooting Sample Preparation

- Due to the biological variability among samples and variability in collection methods, standard processes may not always yield a satisfactory and uniformly distributed preparation on the first slide



Troubleshooting Sample Preparation

- After staining, you may observe the following irregularities:
 - Non-uniform distribution of cells in the cell spot *without* a “sample is dilute” message
 - Uneven distribution in the form of a ring or halo of cellular material and/or white blood cells
 - A sparse cell spot lacking in cellular component and containing blood, protein and debris – may be accompanied by a “sample is dilute” message



Techniques Used in Troubleshooting

- Diluting the Sample 20 to 1
- Glacial Acetic Acid Wash for Blood and Non-Cellular Debris
- Saline Wash for Protein



Techniques Used in Troubleshooting

- Diluting the Sample 20 to 1
 - Add 1ml of the sample that is suspended in PreservCyt[®] Solution to a new PreservCyt Solution vial (20ml). This is most accurately done with a calibrated pipette



Techniques Used in Troubleshooting

- Glacial Acetic Acid Wash for Blood and Non-Cellular Debris
 - If sample is bloody, it can be further washed using a solution of 9 parts CytoLyt[®] Solution



and 1 part Glacial Acetic acid

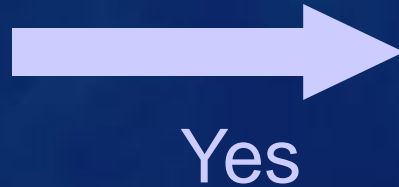
Techniques Used in Troubleshooting

- Saline Wash for Protein
 - If sample contains protein, it can be further washed with saline solution in place of CytoLyt[®] Solution



Troubleshooting Bloody or Proteinaceous Specimens

“Sample is Dilute”
message



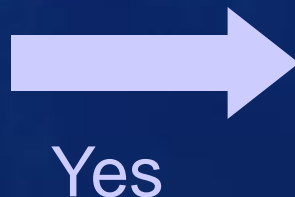
Check to see if
cellularity is adequate.
If not, use more of the
pellet, if available and
prepare new slide



No, continue to
next slide

Troubleshooting Bloody or Proteinaceous Specimens

Does the slide have a
“halo” of cellular
material and/or white
blood cells?



Dilute 20:1 by adding
1ml of residual sample
to a new PreservCyt®
Solution Vial and
prepare new slide

*If halo is present on the
new slide, contact
Hologic® Technical
Service.*



No, continue to next
slide

Troubleshooting Bloody or Proteinaceous Specimens

Is the slide sparse and does it contain blood, protein or non-cellular debris?



No

**Contact Hologic®
Technical Service**

**Yes-blood
or non-
cellular
debris**

Centrifuge remaining specimen from PreservCyt® vial, pour off and vortex. Add 30ml of a 9:1 CytoLyt® to glacial acetic acid solution to the sample, centrifuge, pour off and vortex. Add to appropriate number of drops to PreservCyt vial and prepare new slide. *If the resulting slide is sparse, contact Hologic Technical Service.*

Yes-protein

Centrifuge remaining specimen from PreservCyt vial, pour off and vortex. Add 30 ml of saline to sample, centrifuge, pour off and vortex. Add appropriate number of drops to PreservCyt vial and prepare new slide. *If resulting slide is sparse, contact Hologic Technical Service.*

Troubleshooting Common Artifacts

- Smudged Nuclear Detail
- Compression Artifact
- Staining Artifact
- Edge of the Cylinder Artifact



Troubleshooting Common Artifacts

- Smudged Nuclear Detail
 - May occur if specimen is collected in saline, PBS or RPMI
 - To avoid this, collect either fresh, CytoLyt® or in PreservCyt® Solution



Troubleshooting Common Artifacts

- Compression Artifact
 - Appears as “air-dry” artifact on the perimeter of the cell spot
 - Due to a compression of cells between the edge of the filter and the glass slide



Troubleshooting Common Artifacts

- Staining Artifact
 - Mimics air drying
 - Appears as a red or orange central staining primarily in cells clusters or groups
 - Due to the incomplete rinsing of the counter stains
 - To eliminate this artifact, fresh alcohol baths or an additional rinse step after the cytoplasmic stains is required



Troubleshooting Common Artifacts

- Edge of the Cylinder Artifact
 - Narrow rim of cellular material just beyond the circumference of the cell spot
 - Results from cells from the outer edge of the wet filter cylinder being transferred to the glass slide



Specimen Types

- Voided Urine
- Catheterized Bladder Urine
- Cystoscopy specimens:
 - a. Bladder Urine
 - b. Bladder Wash
 - c. Ureter or Renal Wash
- Ileal Conduit Urine
- Retrograde Brushing



Voided Urine

- Easily obtained
- Often contaminated with cells from the perineum or the genital tract, particularly in women
- Samples entire urinary tract
- Good sensitivity for high-grade tumors
- Cells can show degeneration
- Low numbers of diagnostic cells may be present, especially in low-grade tumors



Catheterized Bladder Urine

- Sample is collected during simple catheterization
- May see instrumentation effect and/or lubricant material
- Increase in cellularity and preservation over voided specimens
- Lesions in the urethra may be missed
- Pseudopapillary clusters may make the diagnosis of low-grade tumors more difficult



Bladder Urine & Washing

- Bladder urine is collected during cystoscopy followed by a saline wash
- More cellularity than voided specimens
- Method of choice when bladder malignancy is suspected
- Almost no contamination with excellent preservation
- High sensitivity including low-grade tumors
- Risks include infection, spread of tumor, and limited sample area



Retrograde Brushing

- Brush is inserted into the ureter during cystoscopy
- Sampling of the ureter or kidney pelvis
- Able to view suspicious areas with the ureteroscope and take direct sampling
- Risks include bleeding, infection and perforation of the ureter

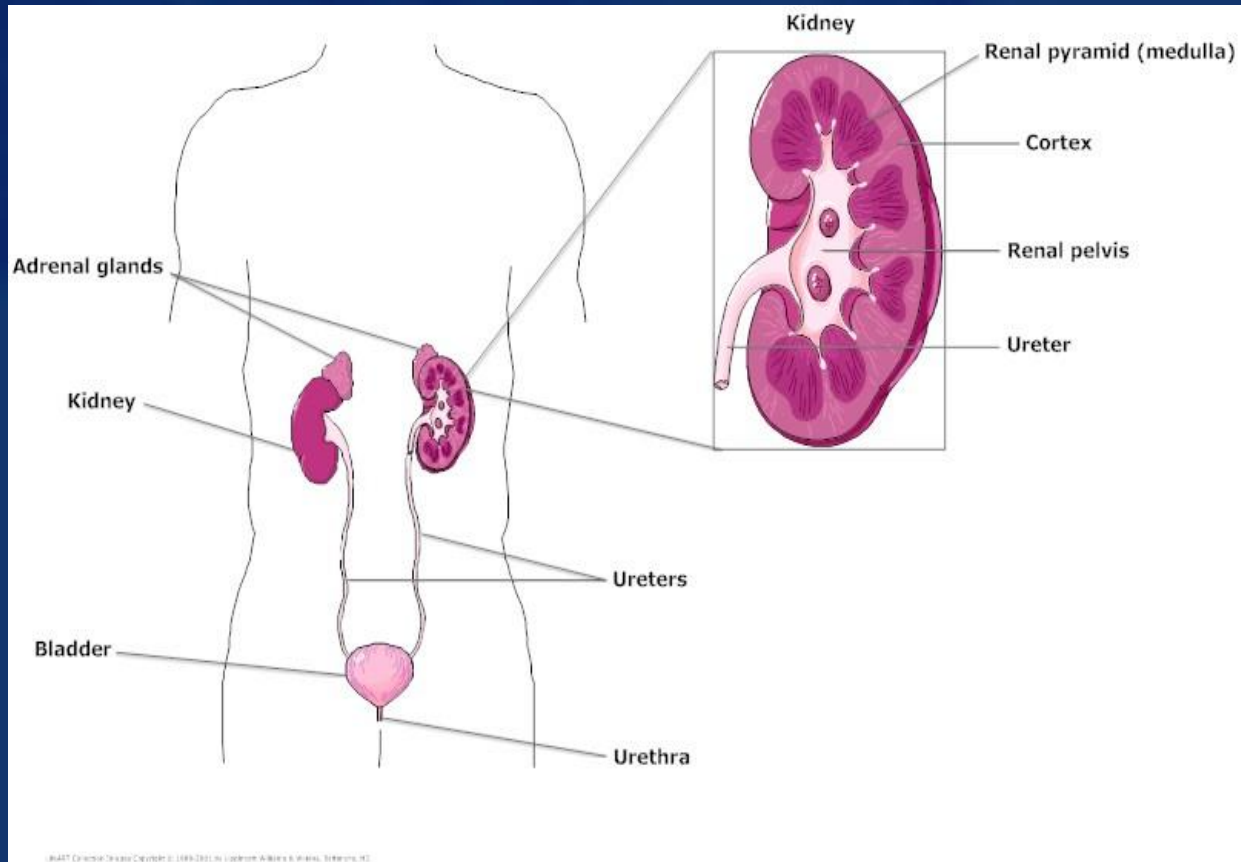


Ileal Conduit/Loop Urine

- During a cystectomy, a portion of the bowel is used as a urine conduit
- Commonly contains:
 - Abundant macrophages, mucus, lymphocytes and PMN's
 - Small intestinal columnar cells
 - These may be seen in honeycombed groups and picket fence arrangements as well as singly
 - They may also appear round and vacuolated

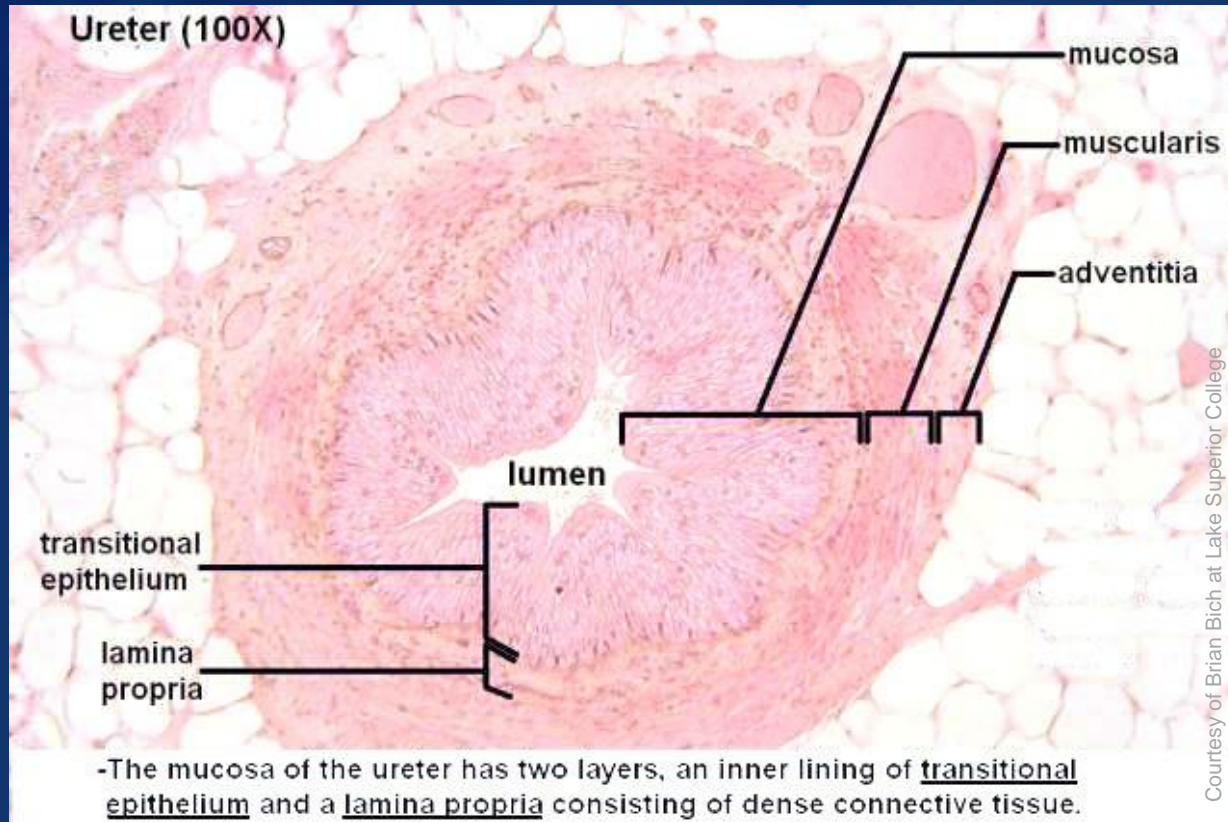


Urinary Tract Anatomy



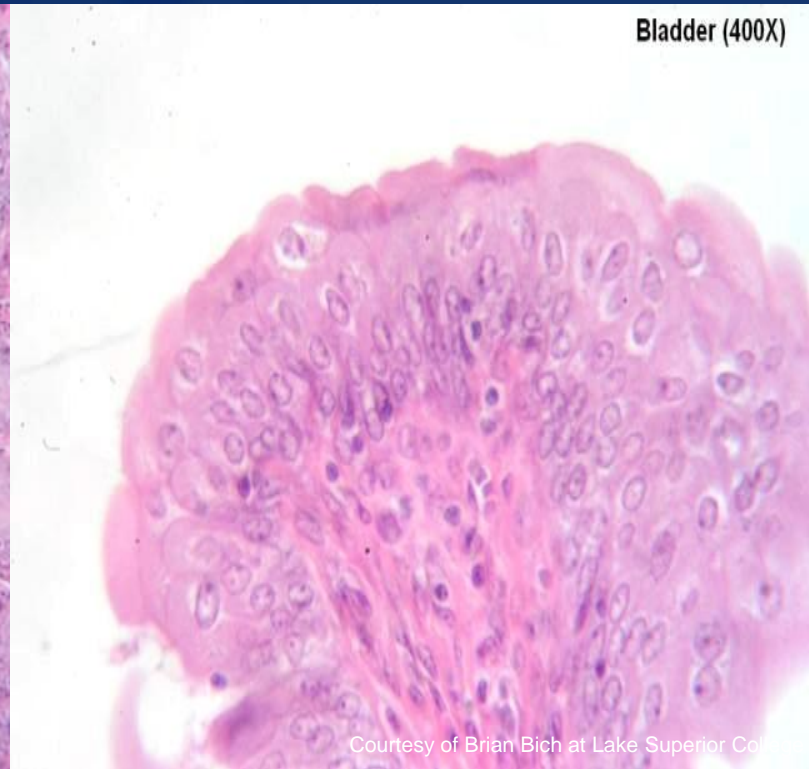
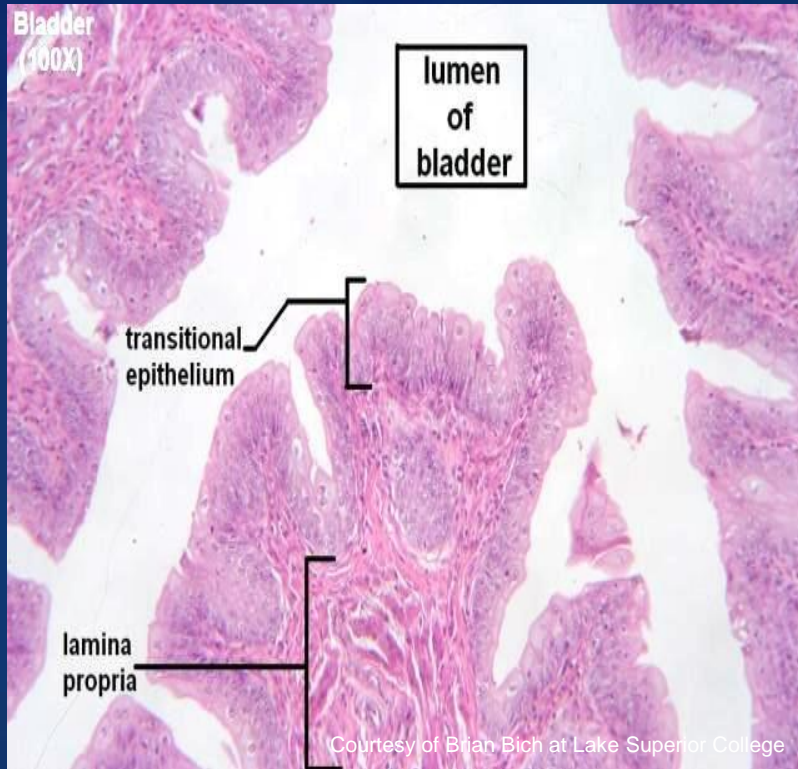
Histology of Epithelium

Ureter



Histology of Epithelium

Bladder



Biological Nature of Urine

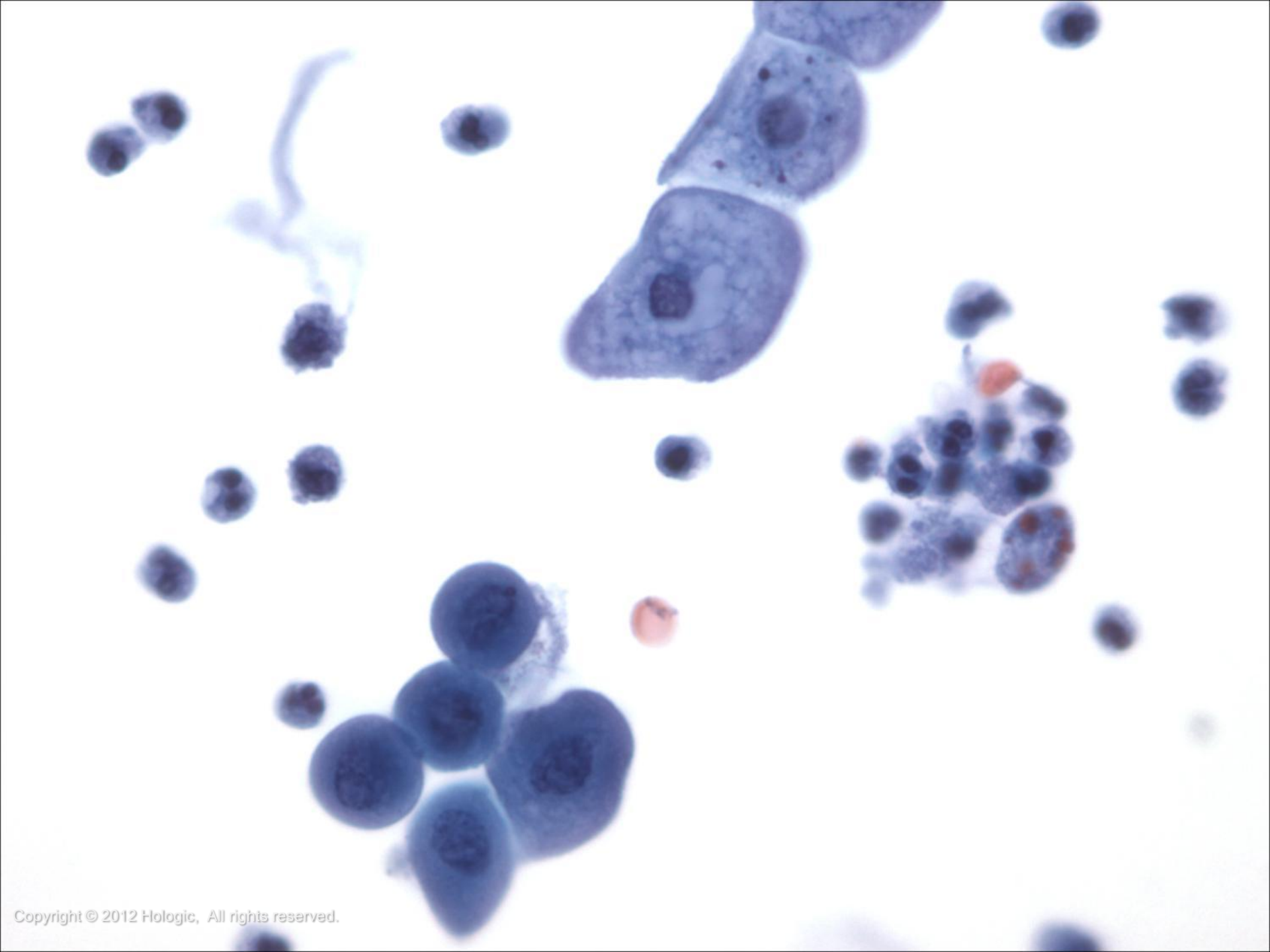
- Contains urea, nitrogen, electrolytes and other organic components
- Specific gravity range of 1.006 to 1.030
- pH range of 4.6 to 8.0

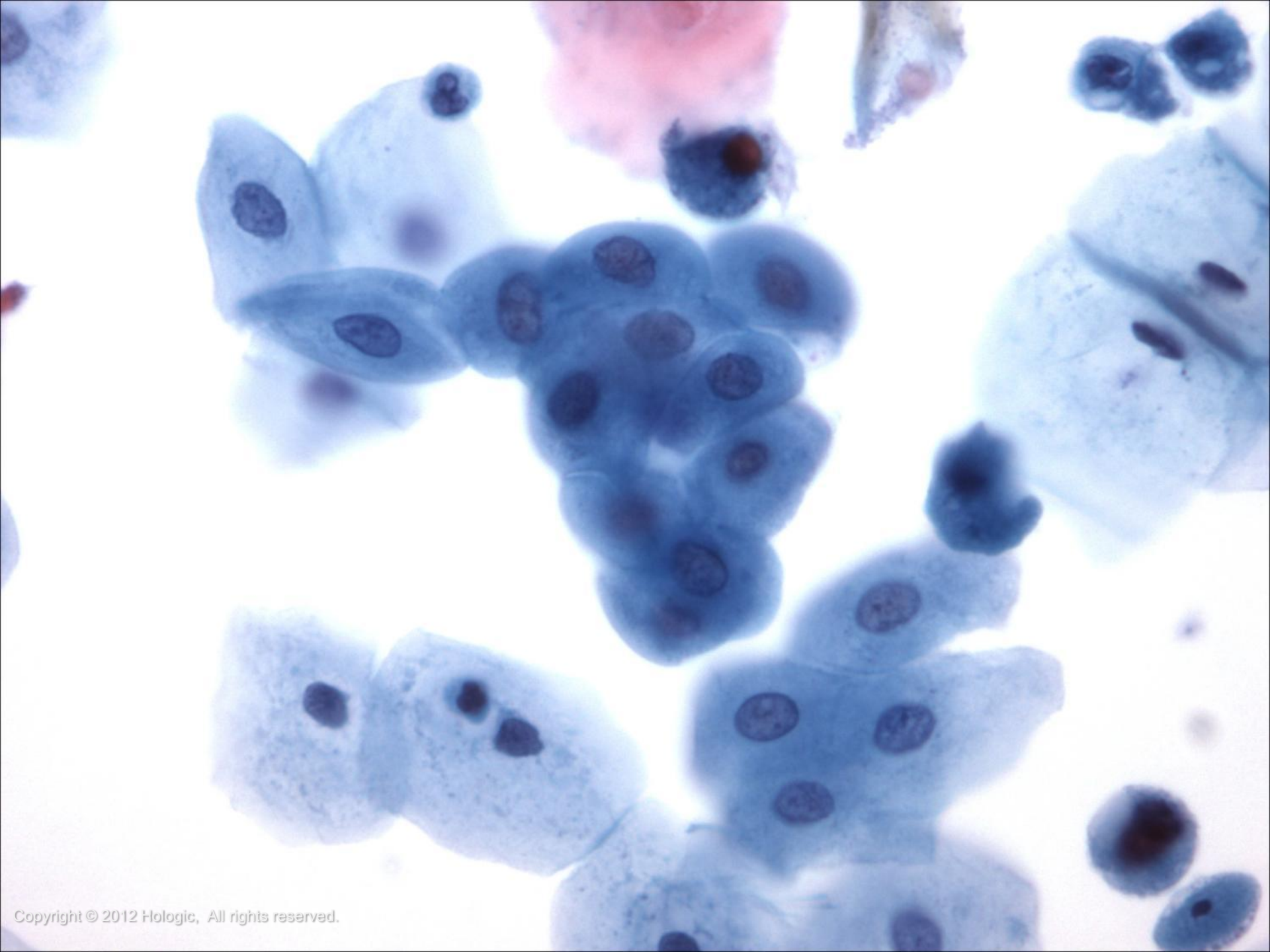


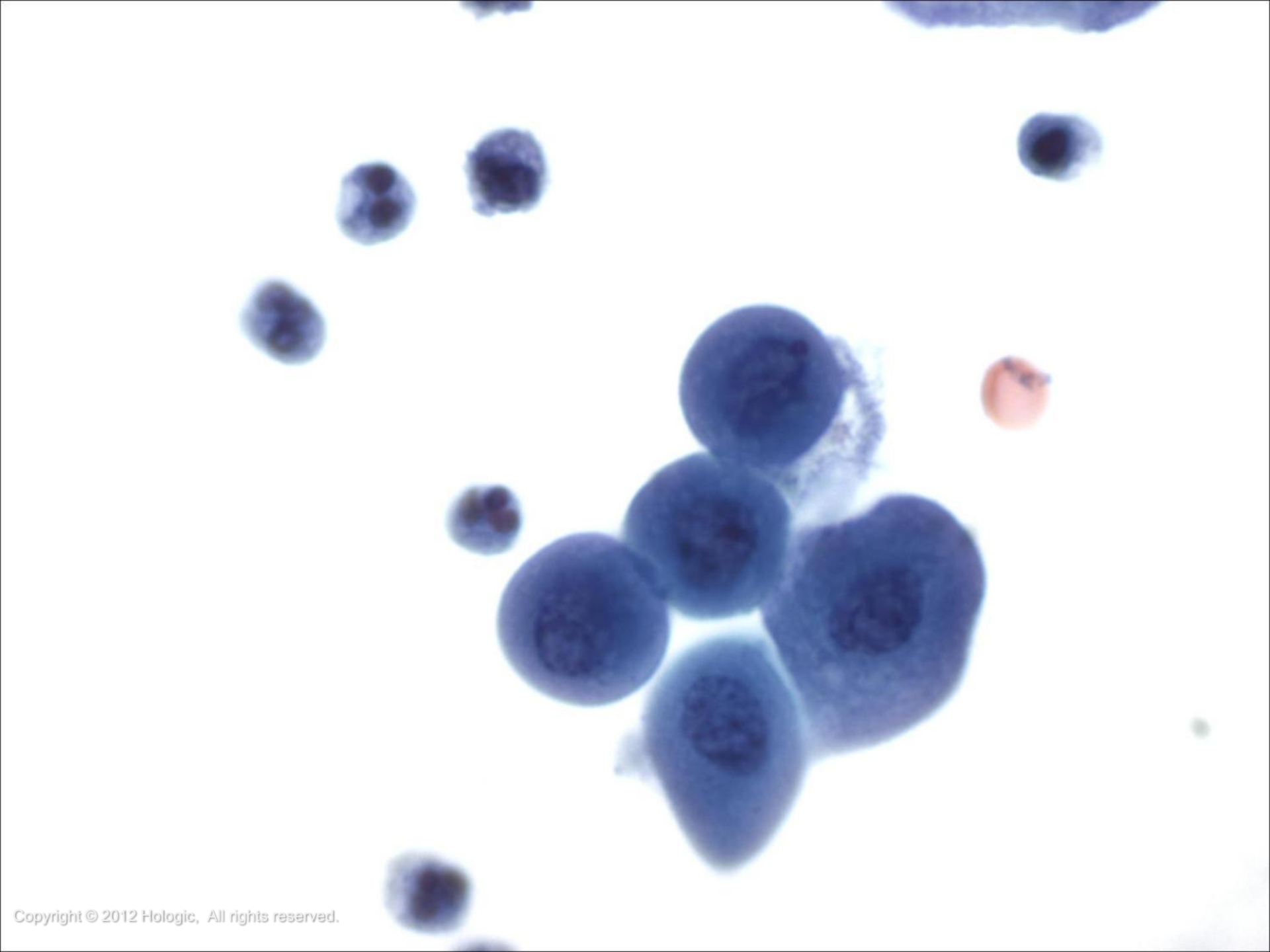
Normal Components and Findings

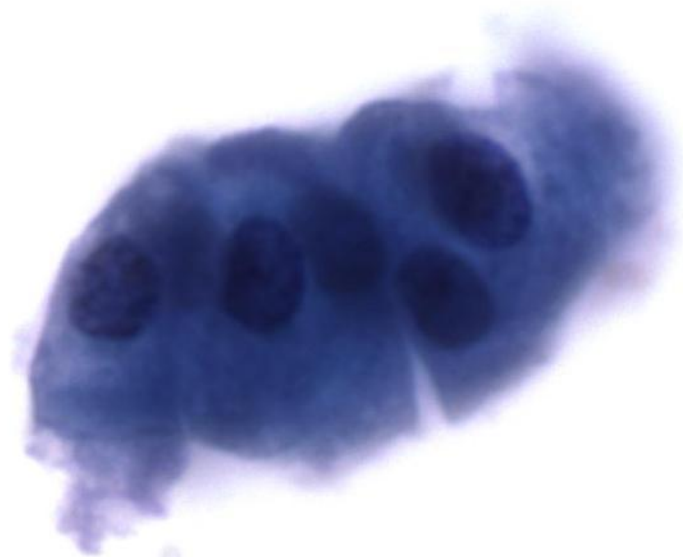- Benign urothelial cells
 - Cytoplasm is abundant and may be foamy to dense
 - Chromatin is finely granular and nucleoli may be present with multinucleation (umbrella cells)

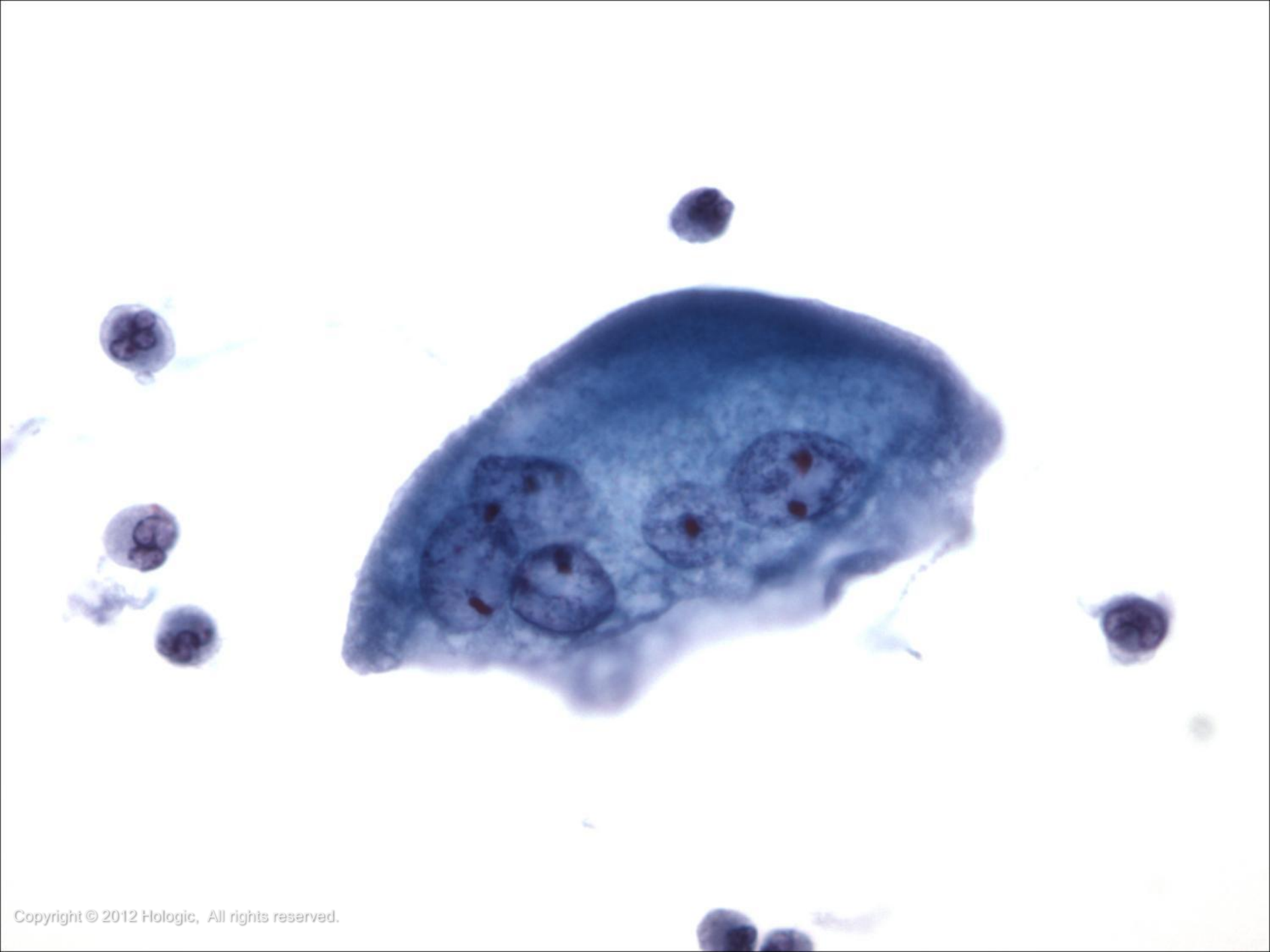








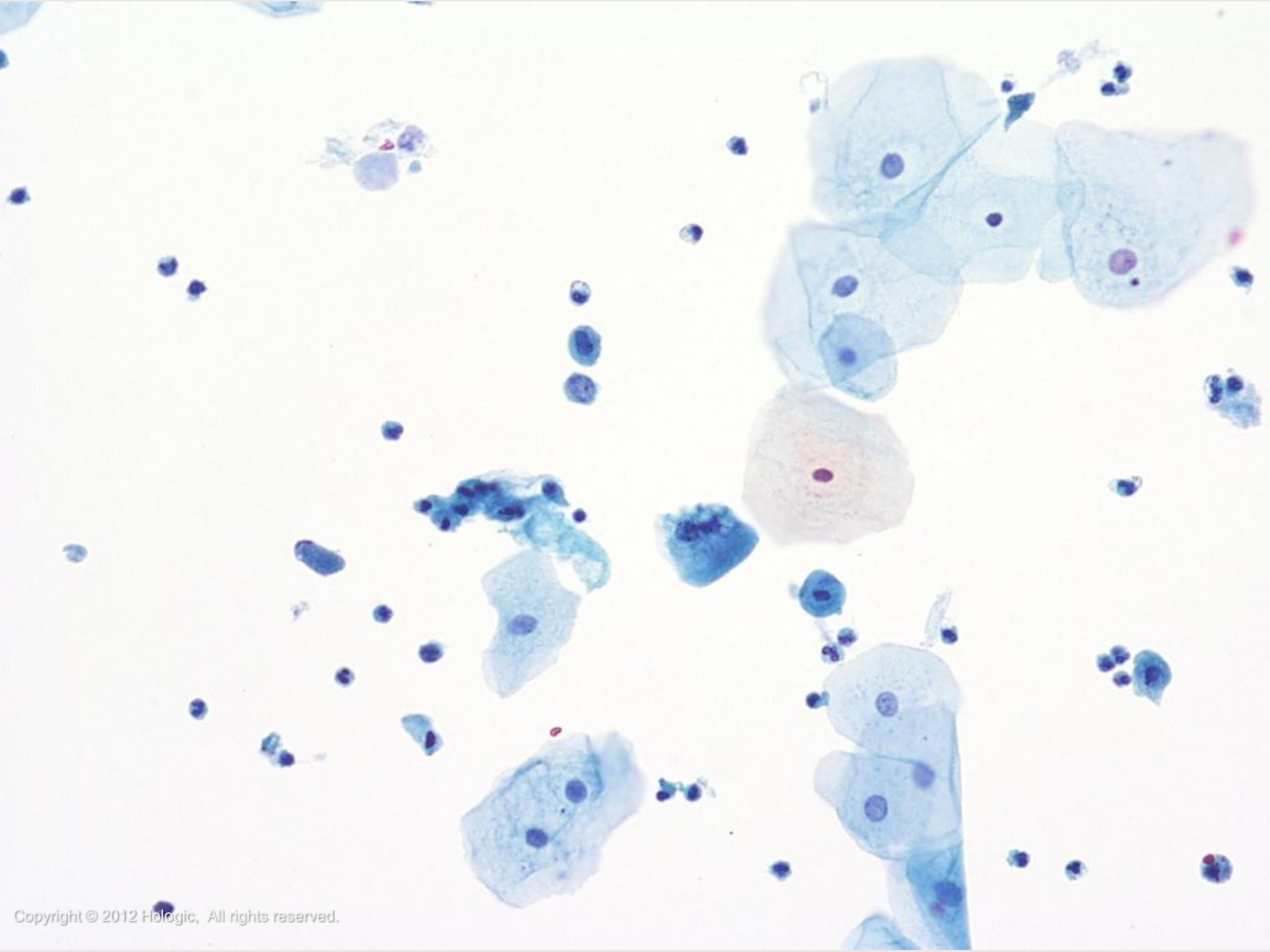


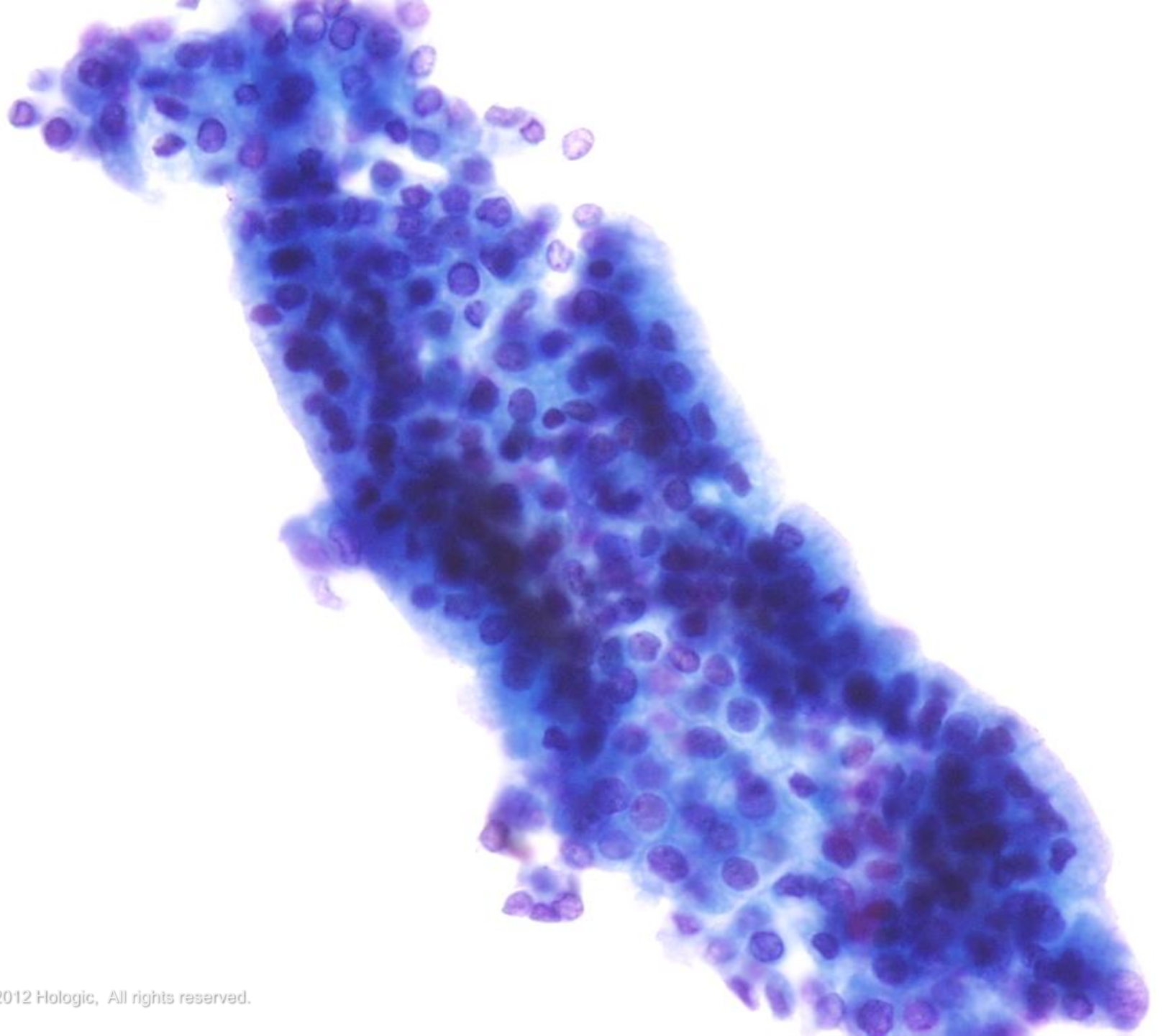


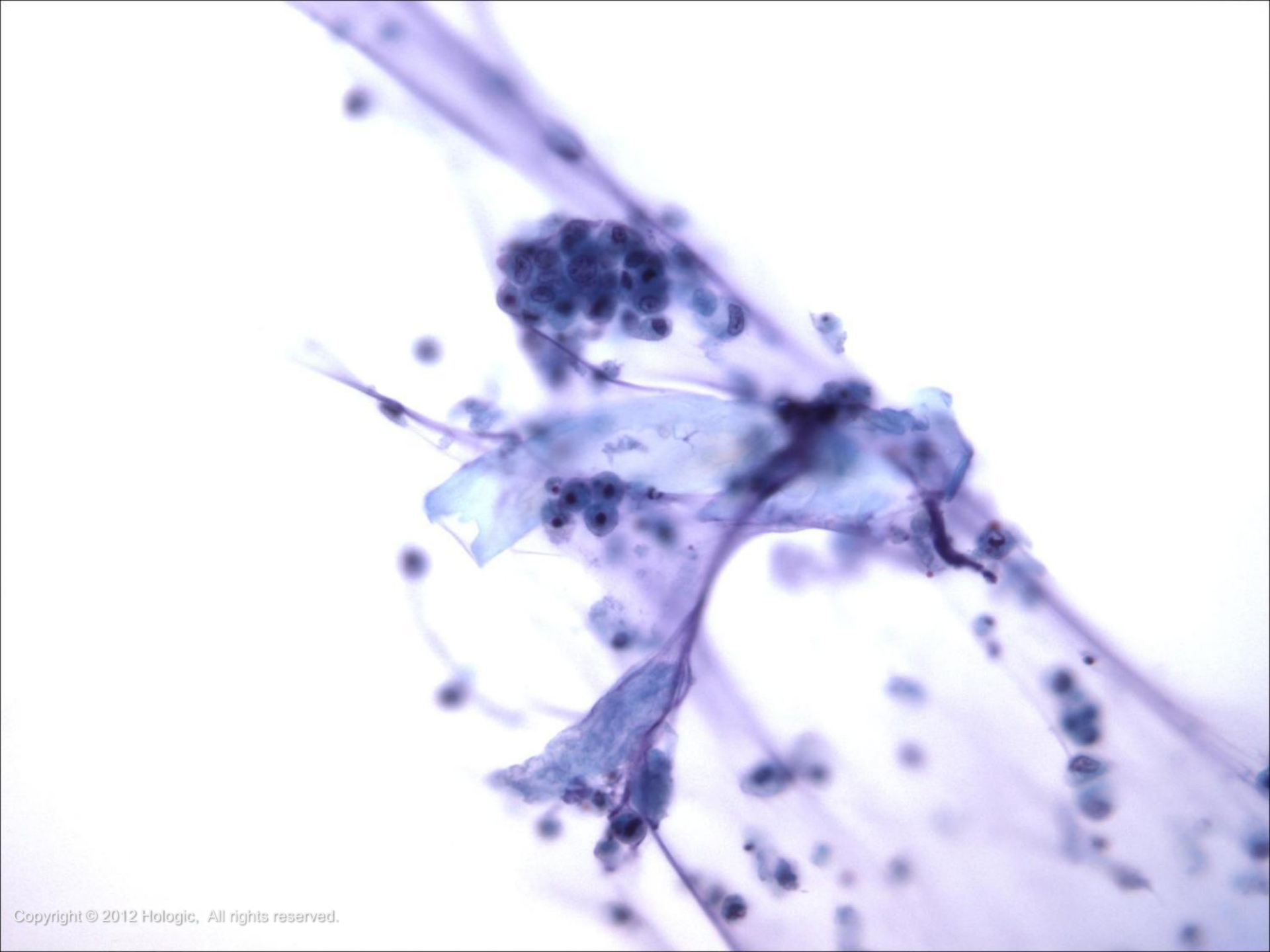
Normal Components and Findings

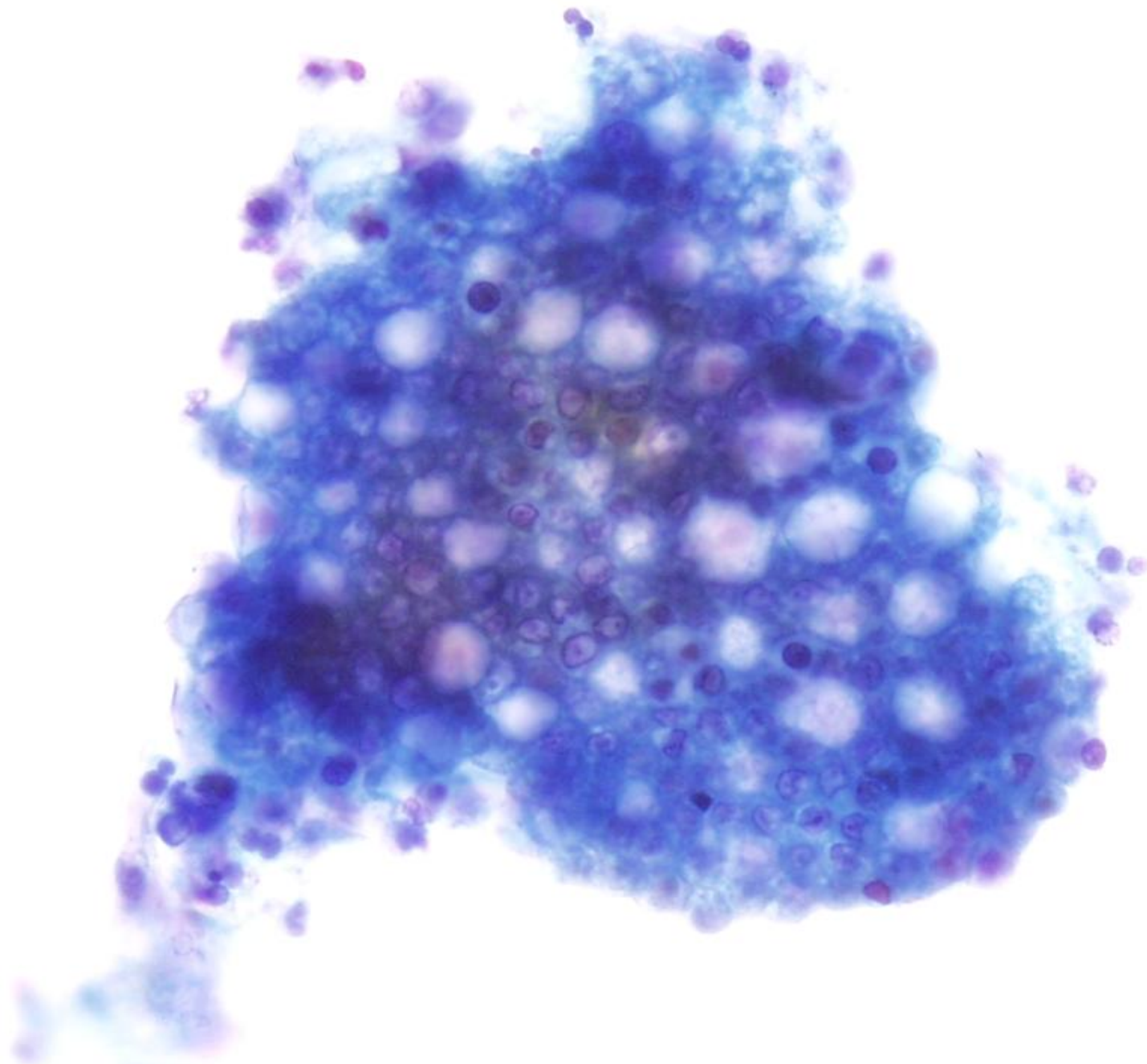
- Benign squamous and glandular cells
 - Benign squamous cells may be shed from the trigone or be present as contaminant
 - Glandular cells may be shed from many sites including the paraurethral and prostate glands and found in loop urines







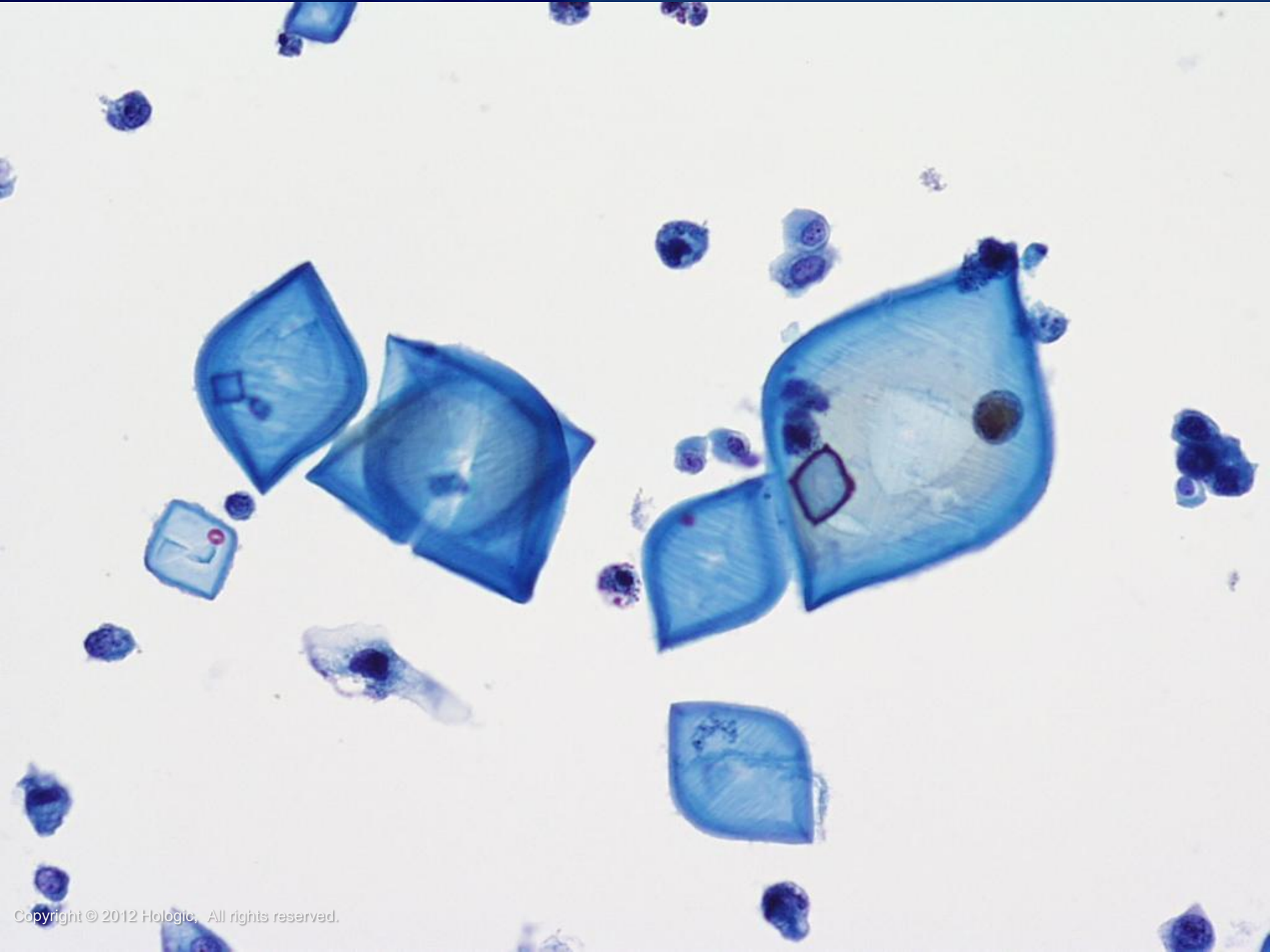


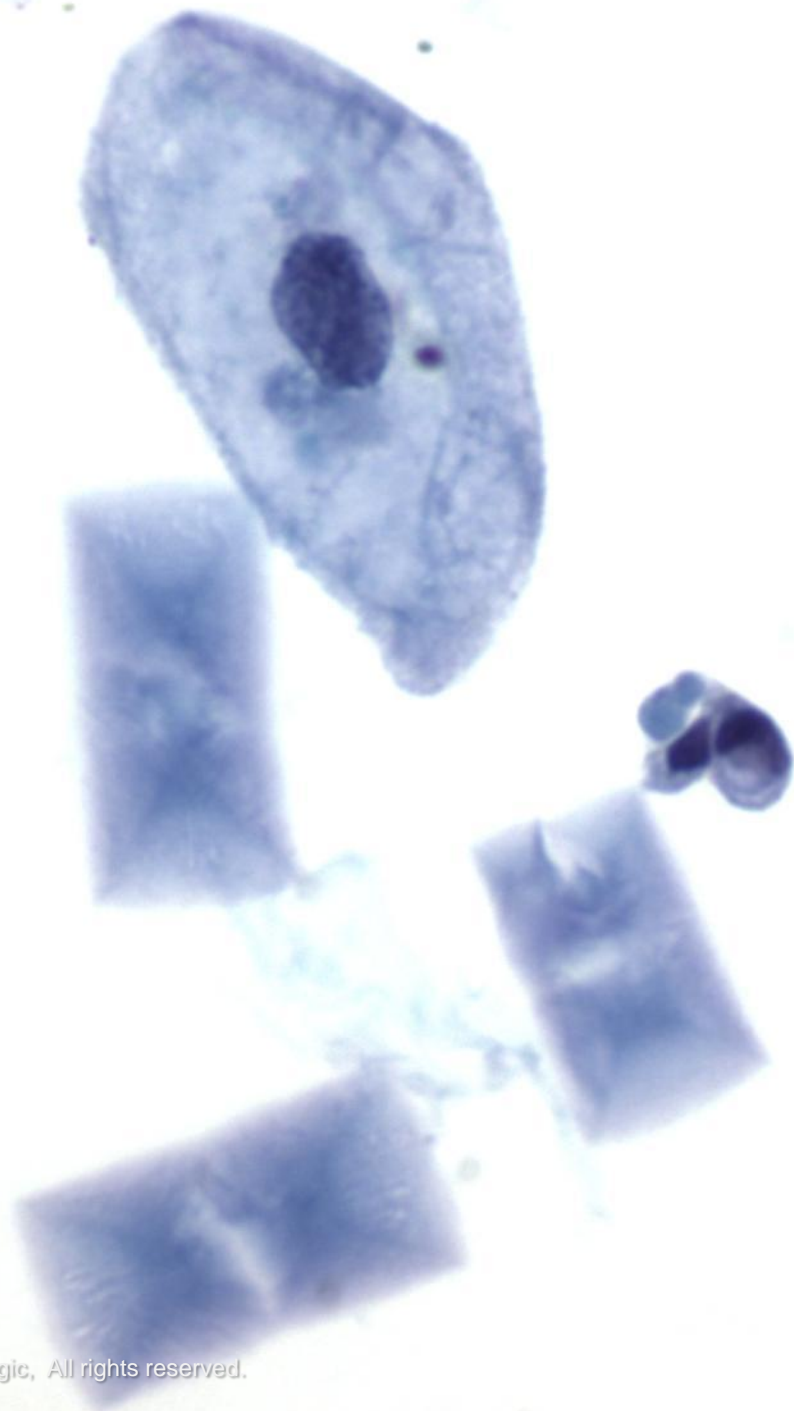



Normal Components and Findings

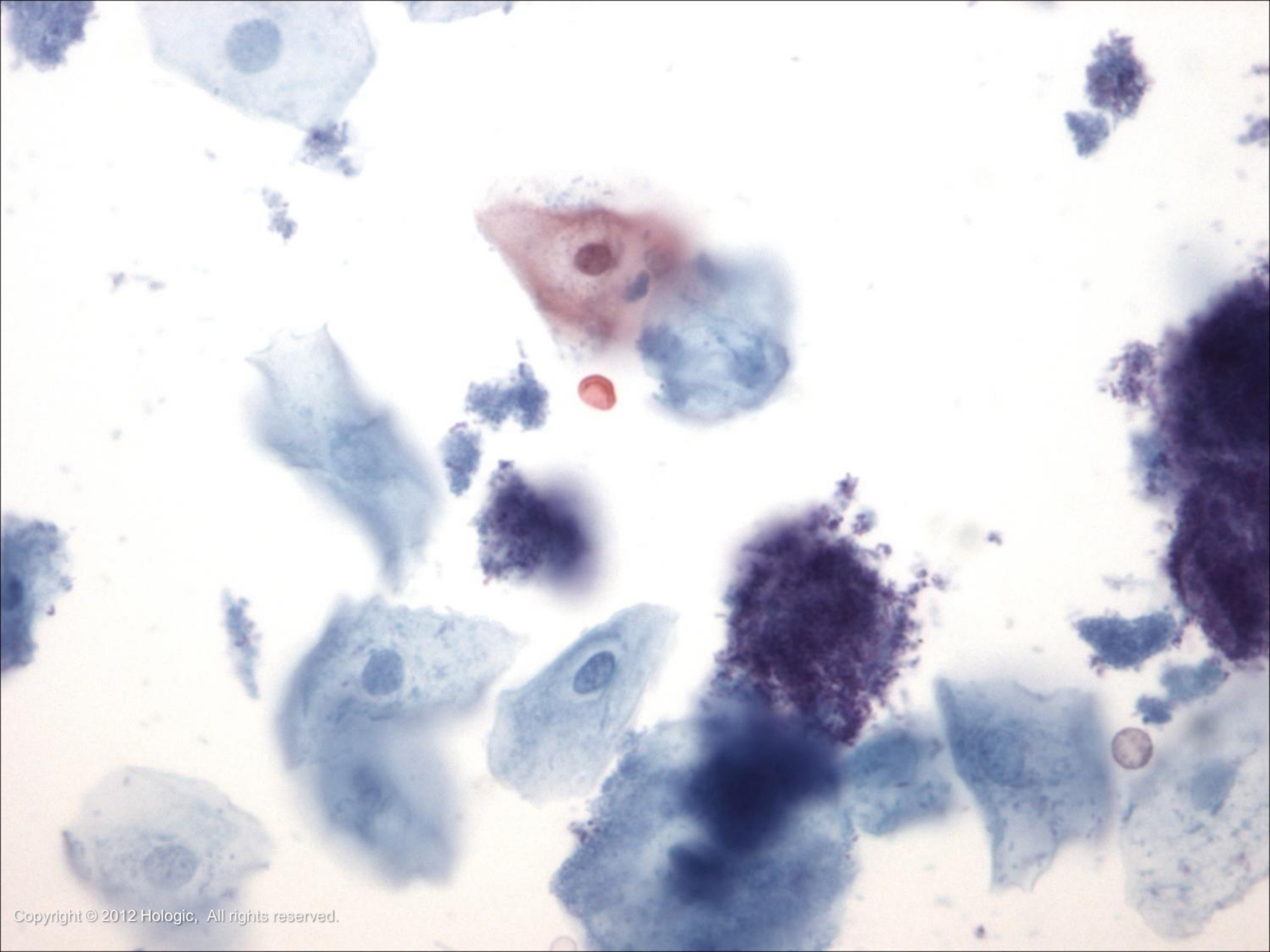
- Crystals
- Contaminants
 - Bacteria and yeast
 - Pollen and talc
 - Spermatozoa and seminal vesicle cells
 - Lubricant
 - Corpora amylacea




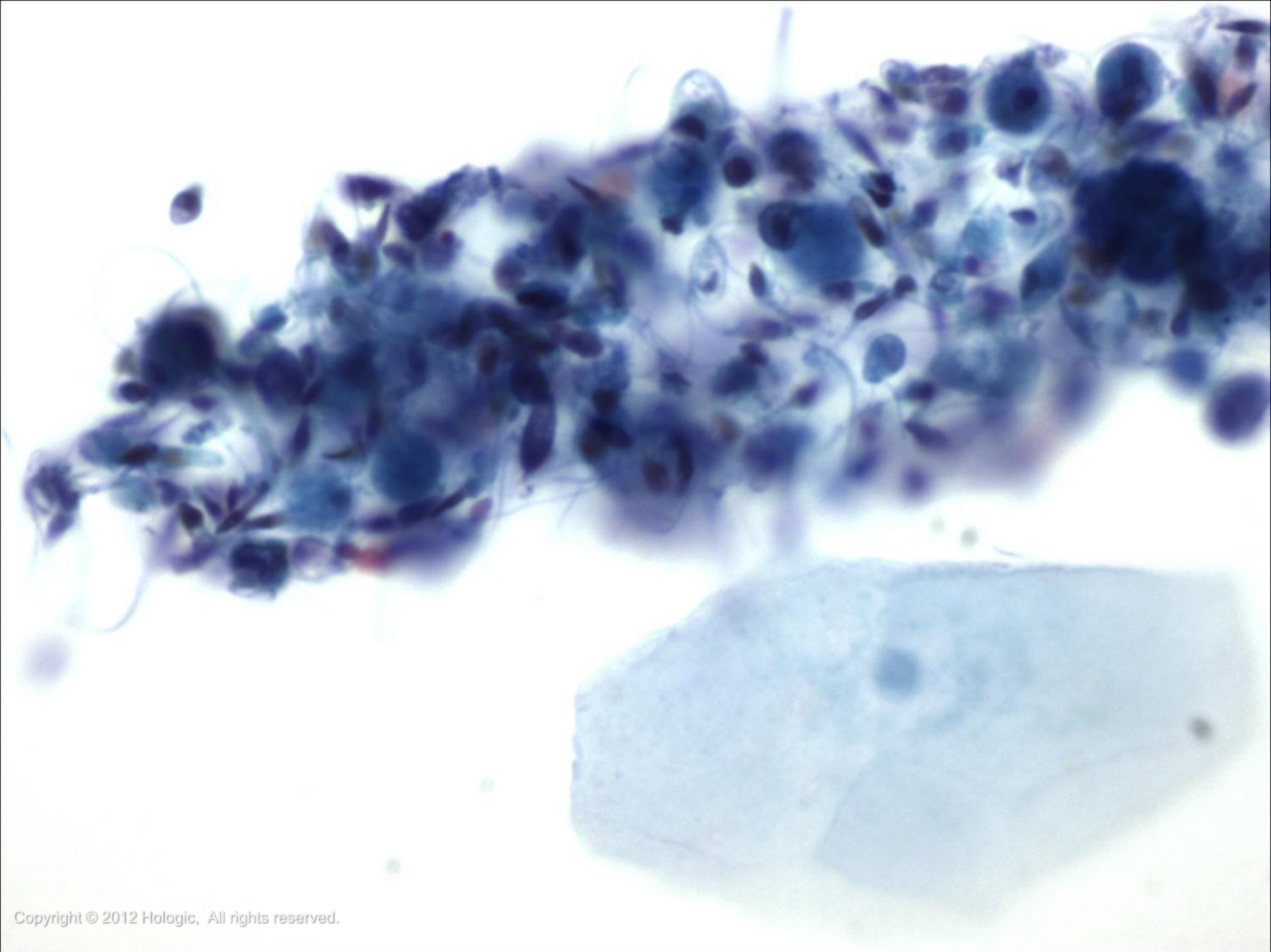


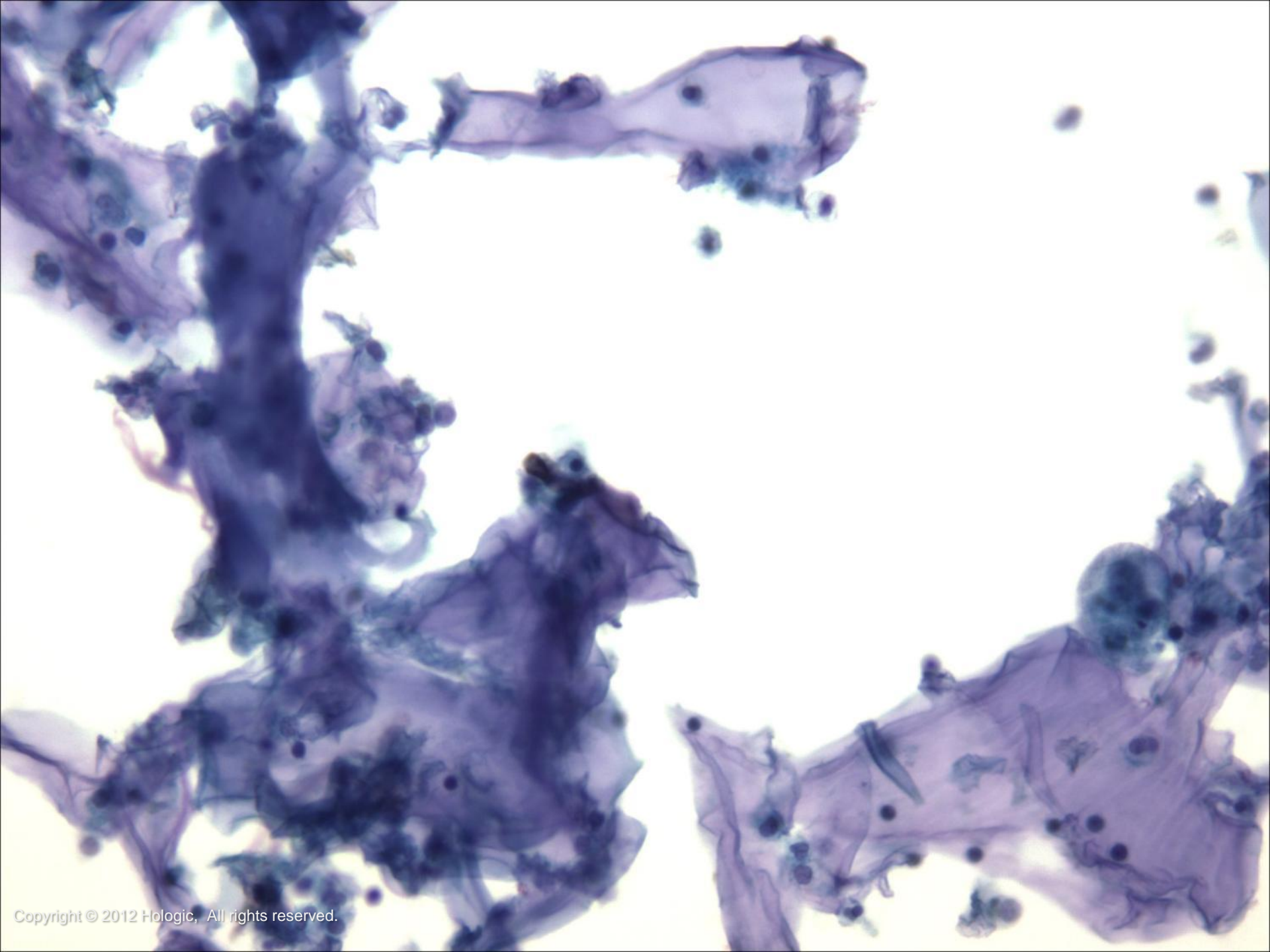











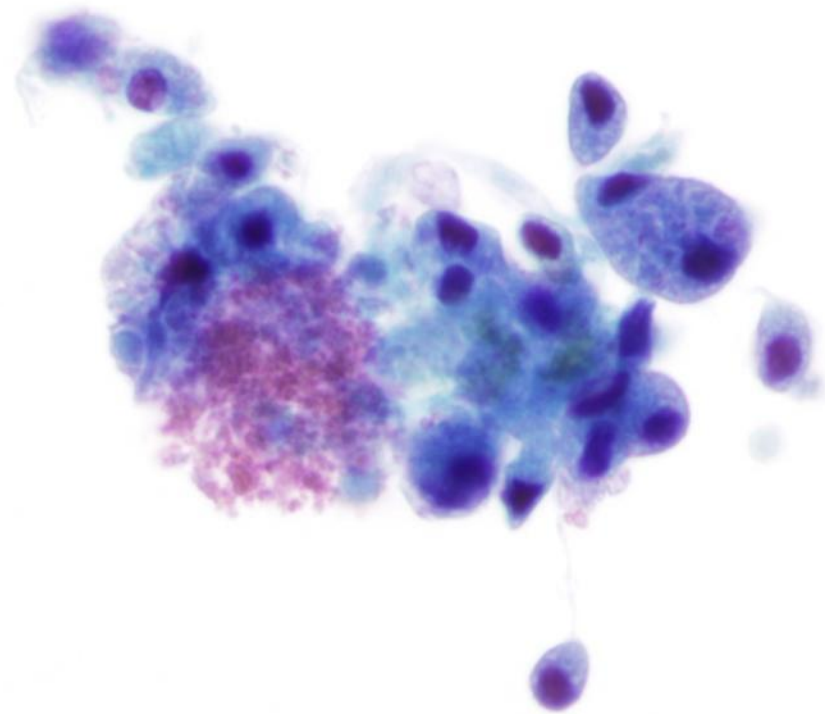


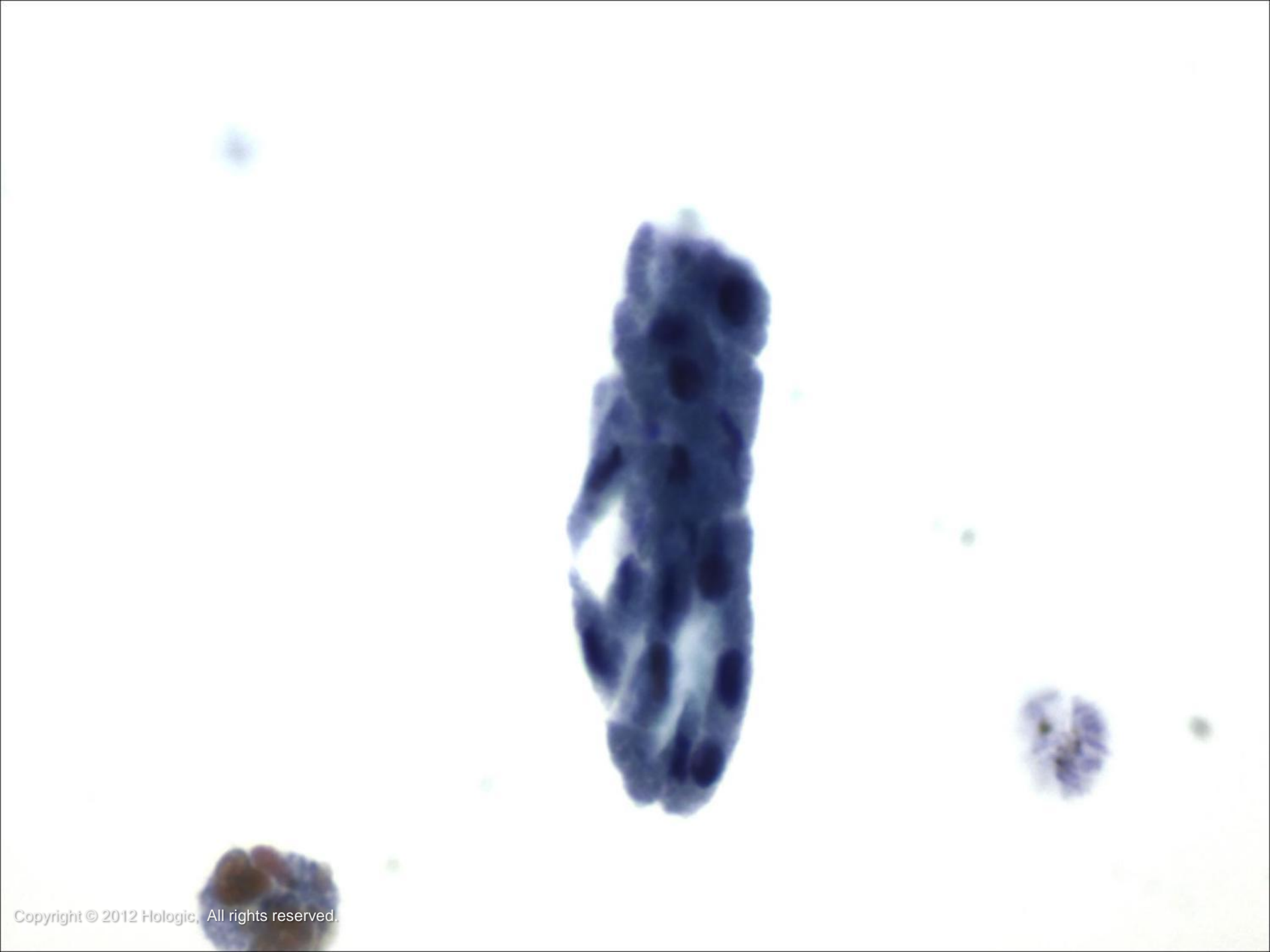


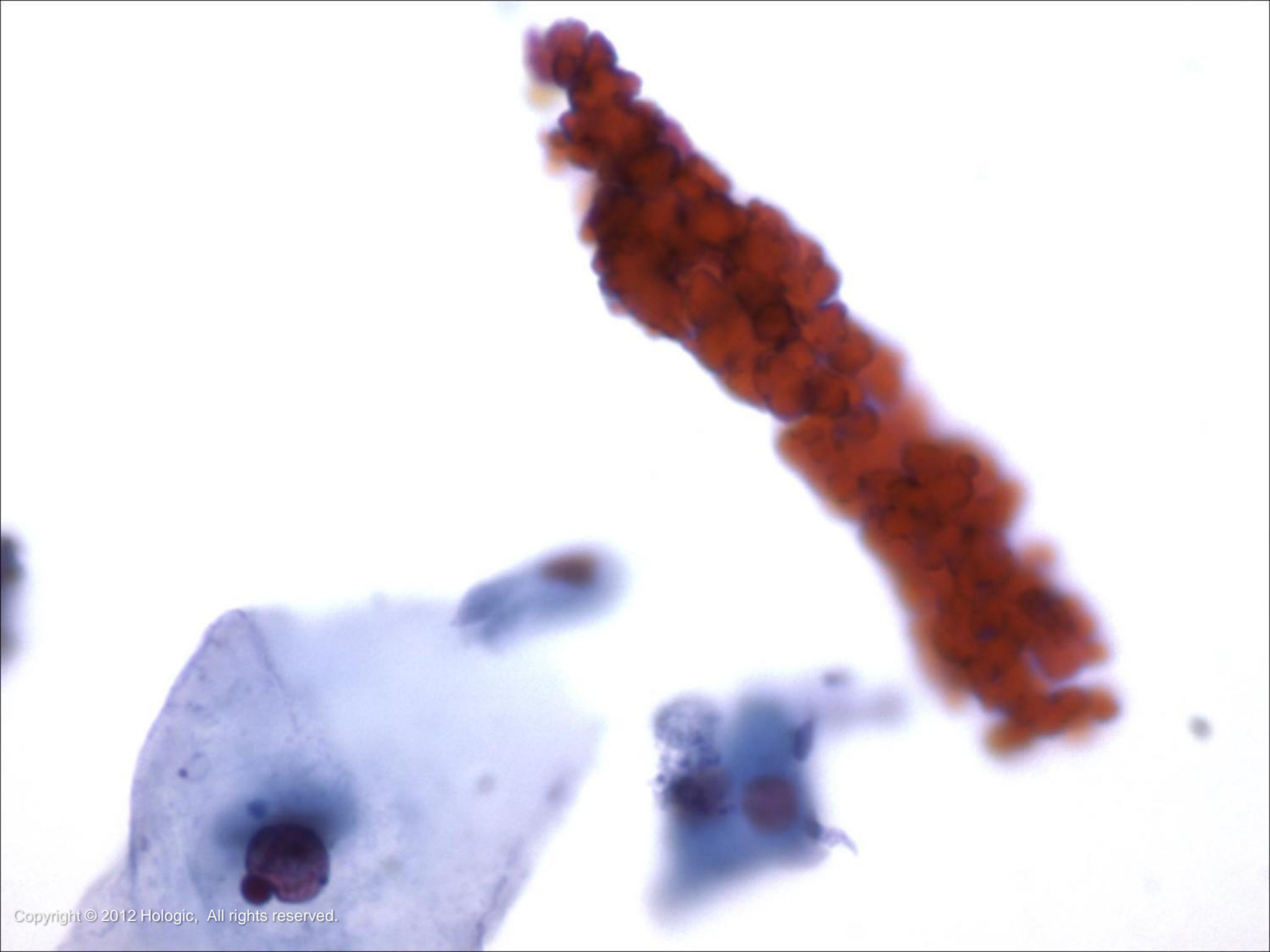
Other Disease Findings

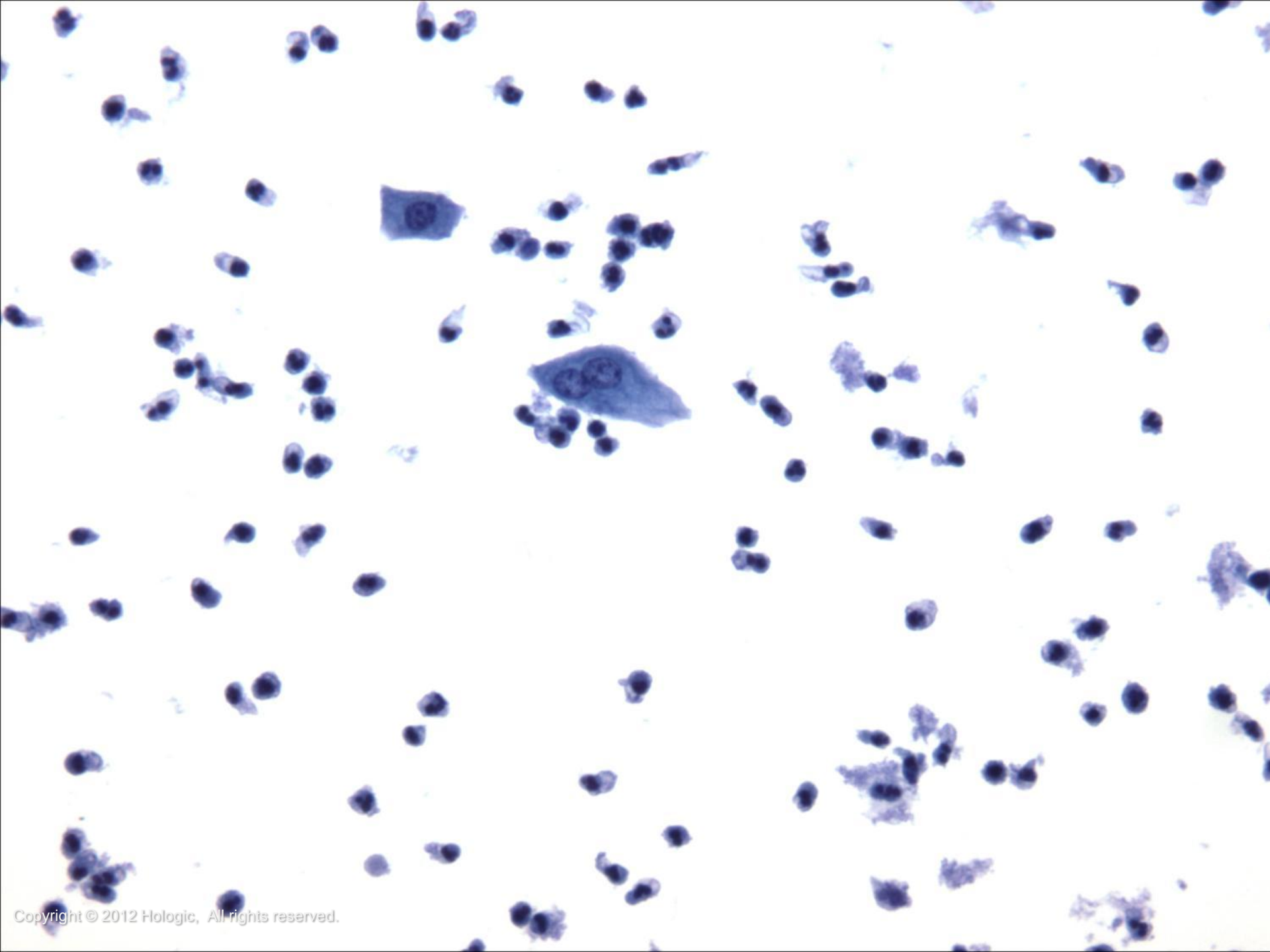
- Renal Tubular Cells
 - Small columnar cells occurring singly, in small sheets or as a granular cast
 - Their presence is associated with kidney disease
- Casts
 - Their presence may be associated with kidney disease, infection and/or bleeding in the kidney
 - May be filled with RBC's, WBC's, degenerated renal tubular cells (granular) or amorphous, eosinophilic proteinaceous material (hyaline)
- Inflammation and RBC's
 - May represent trauma, infection or tumor. Eosinophils may be associated with drug induced interstitial cystitis











Benign Entities and Changes

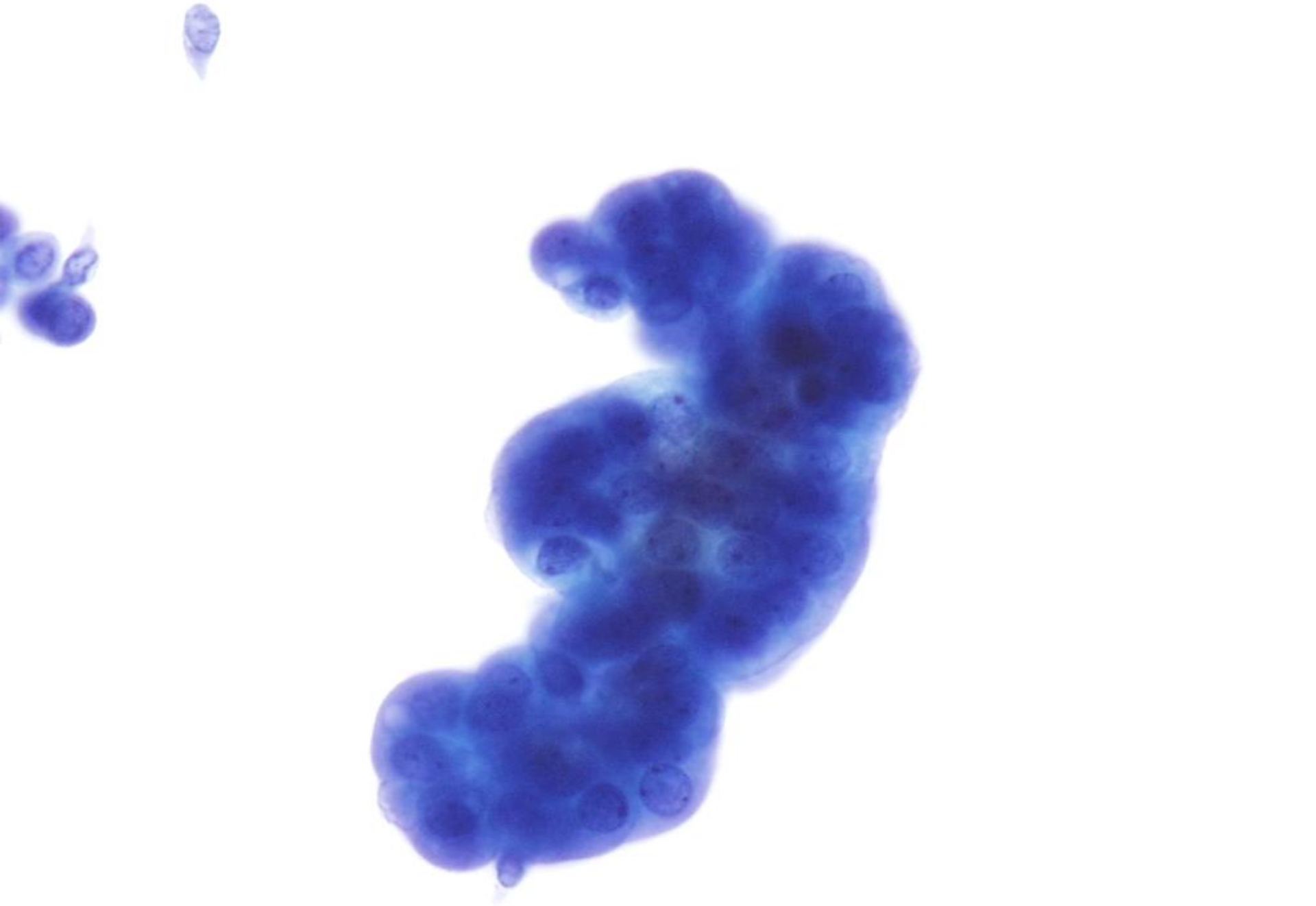
- Reactive changes are very common findings in urinary cytology and may be due to:
 - Instrumentation
 - Infection/Inflammation
 - Drug therapy
 - Calculi

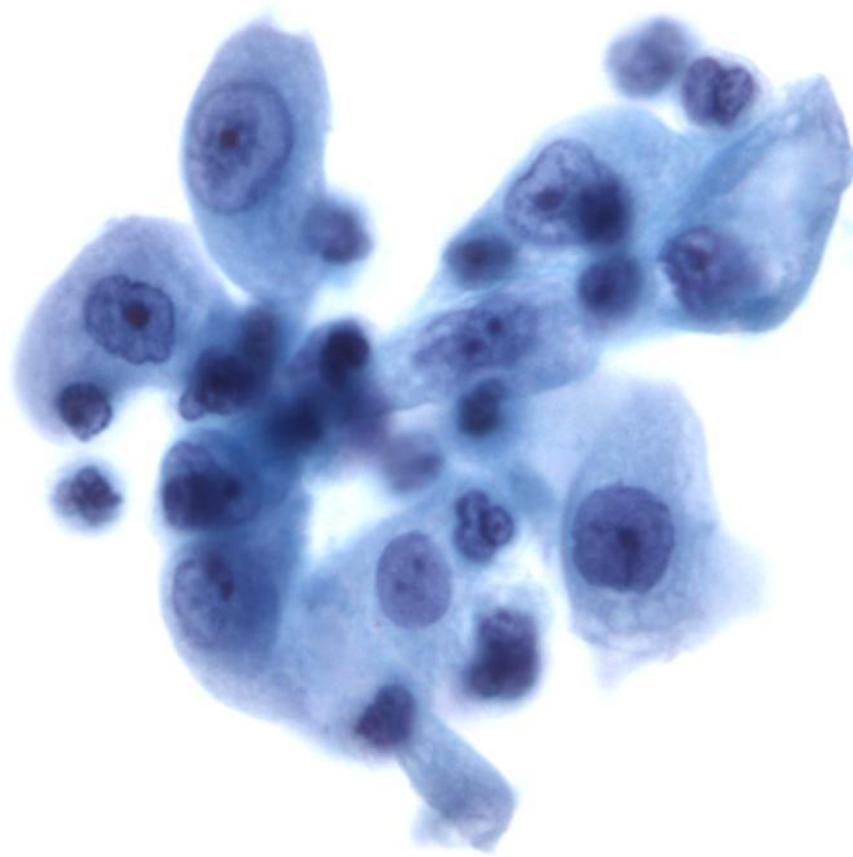


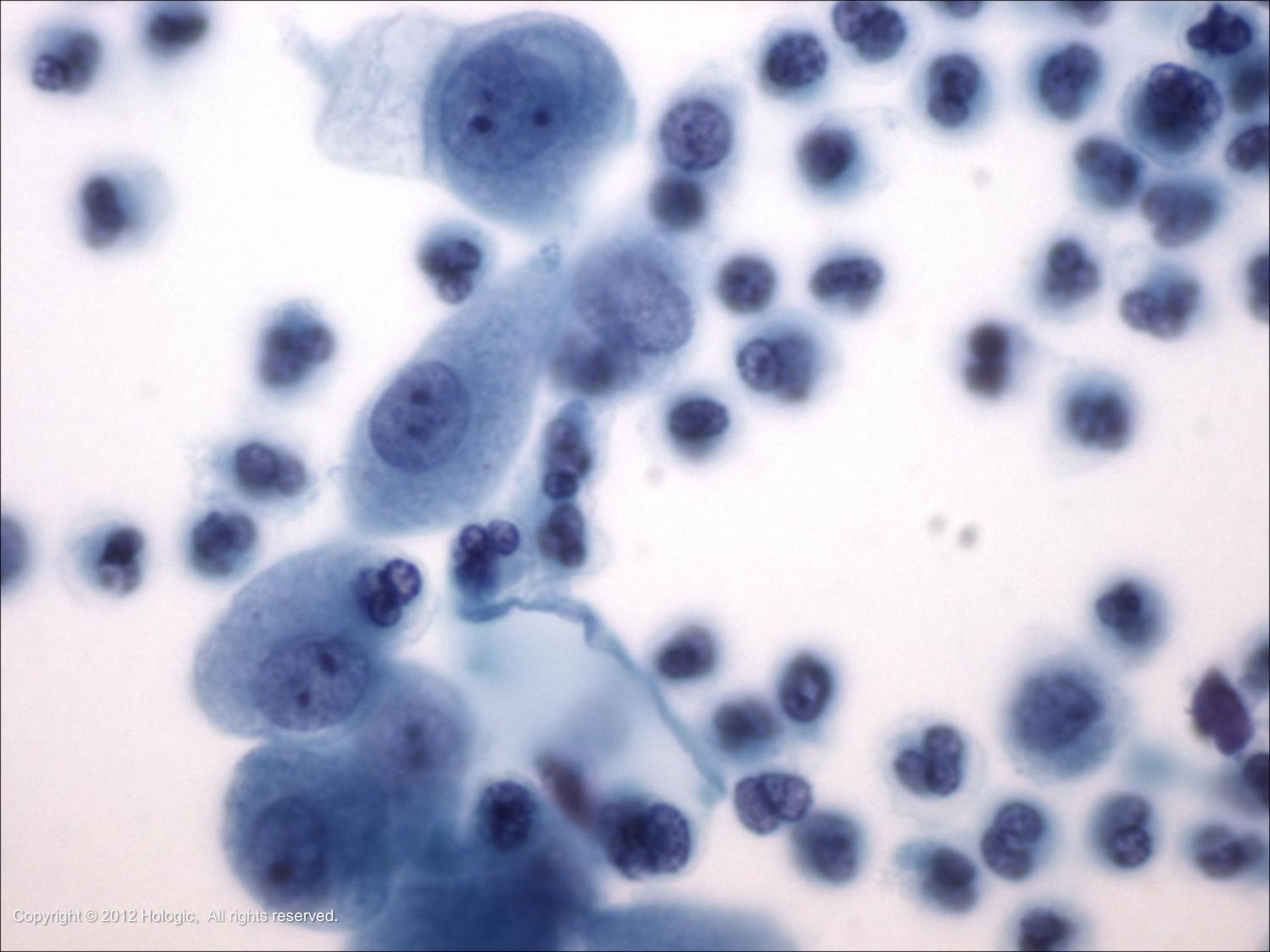
Reactive Changes

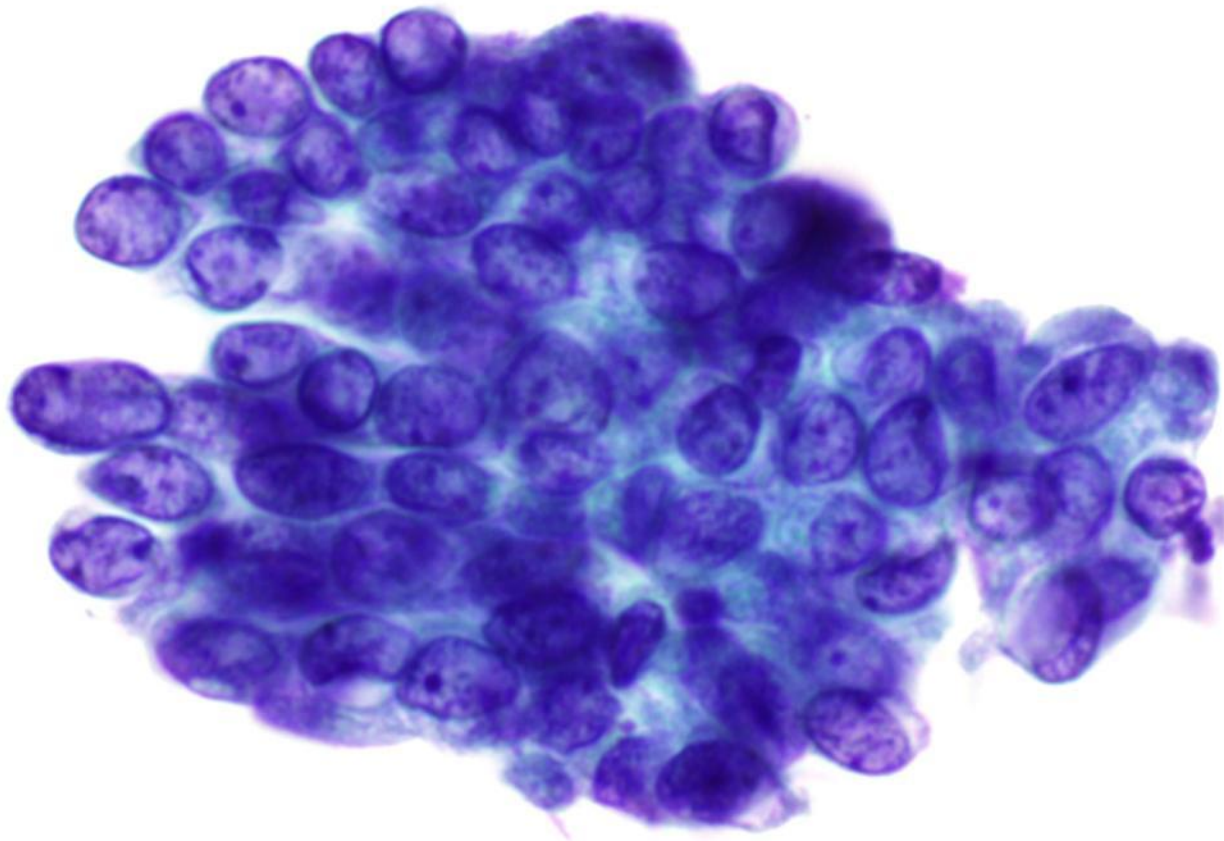
- Features of reactive urothelial cells may include:
 - Marked cellular and nuclear enlargement
 - Prominent nucleoli
 - Coarser chromatin pattern
 - Multinucleation
 - Abundant cytoplasm remains
 - Large honeycombed sheets (especially with instrumentation)

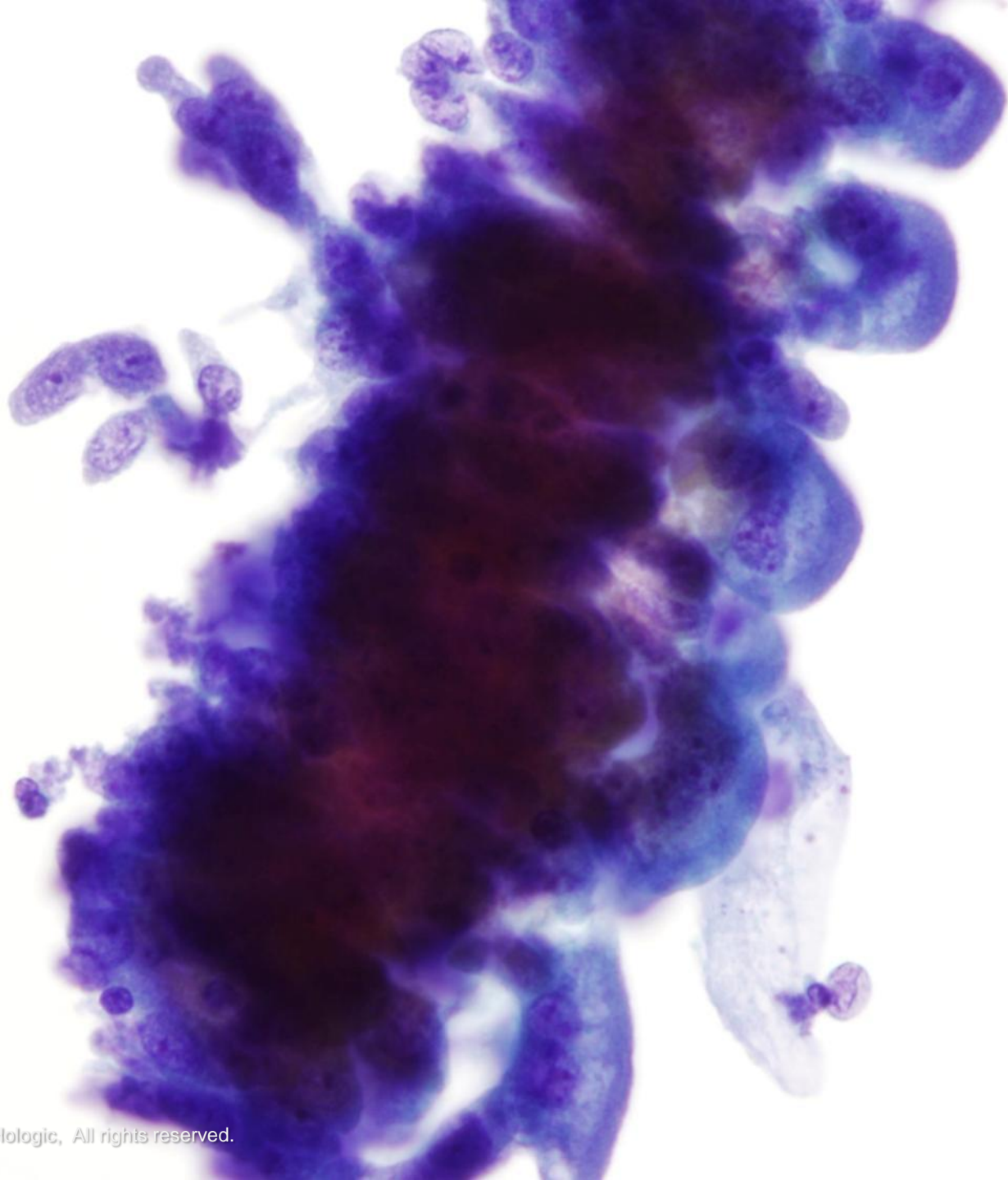












Benign Entities and Changes

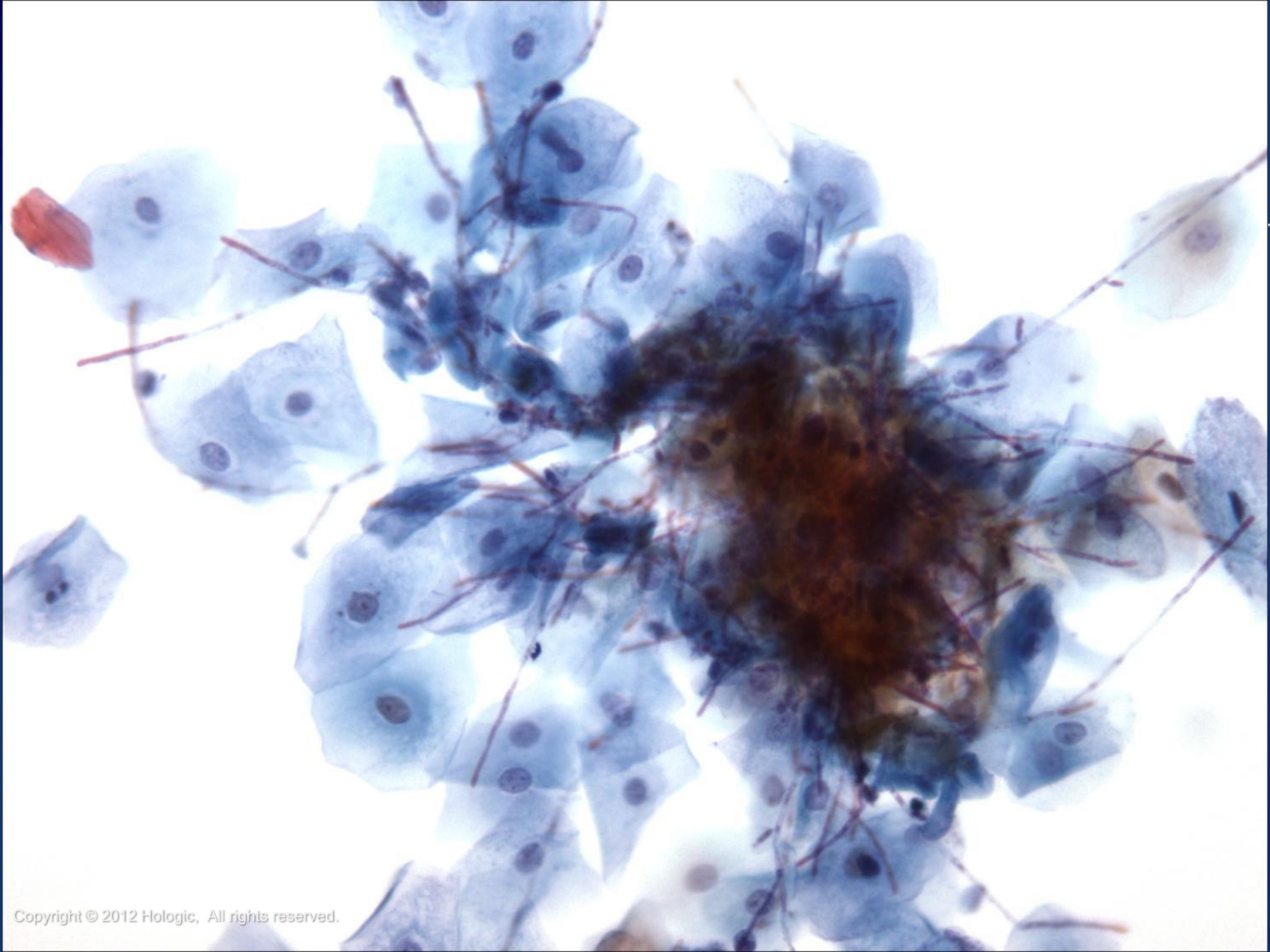
- Infectious agents that may be seen in specimens from the urinary tract may include:
 - Bacteria (most commonly *E. Coli* or streptococcus)
 - Candida
 - Polyoma Virus
 - CMV
 - Trichomonads



Candida

- Candida may be in the form of spores and/or the traditional septate, branching filaments
- It is very often seen as a contaminant from the female genital tract or external genitalia
- It can be the source of an infection, especially in an immune compromised patient

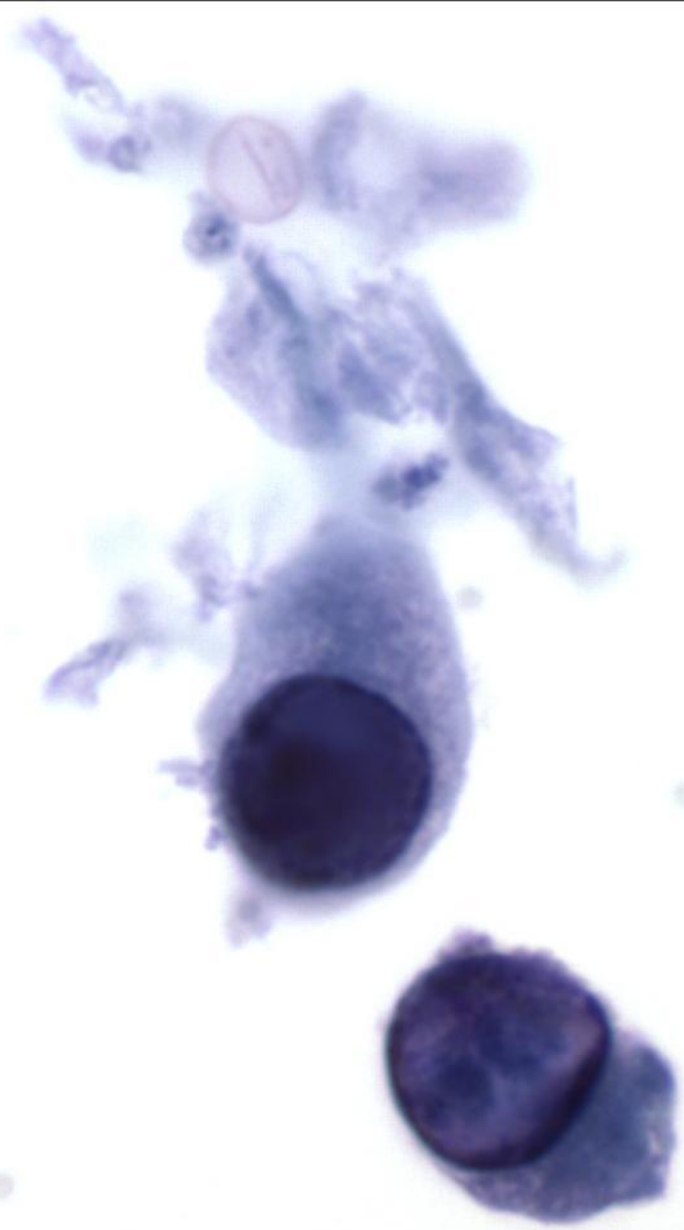


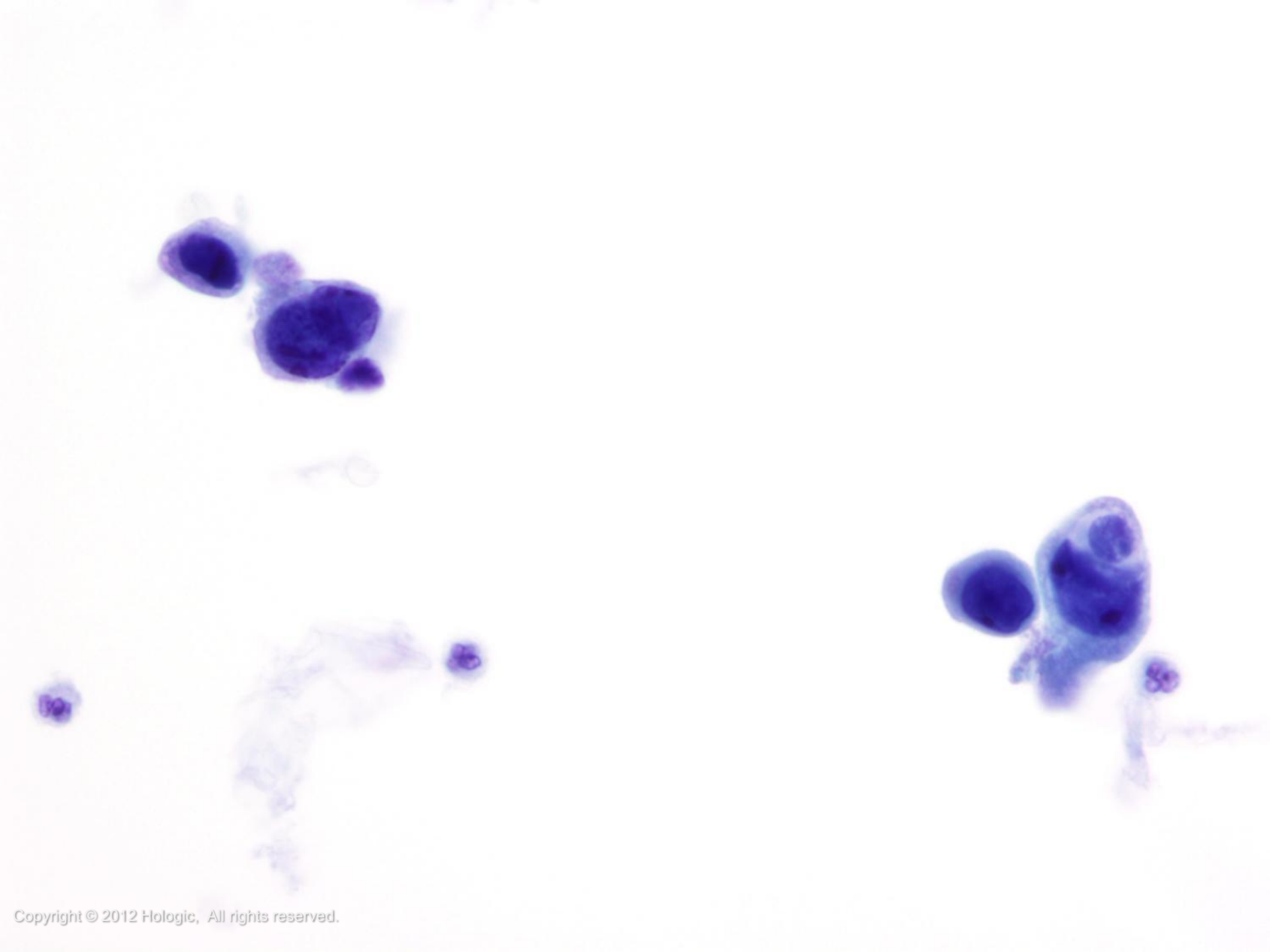


Polyoma Virus

- Polyoma virus can present a diagnostic challenge, as cells infected with the virus (decoy cells) can mimic malignancy
- Decoy cells are commonly plasmacytoid cells with eccentrically placed nuclei
- The virus causes a basophilic intranuclear inclusion, which often appears very dense and dark with a smooth nuclear membrane







Cytomegalovirus (CMV)

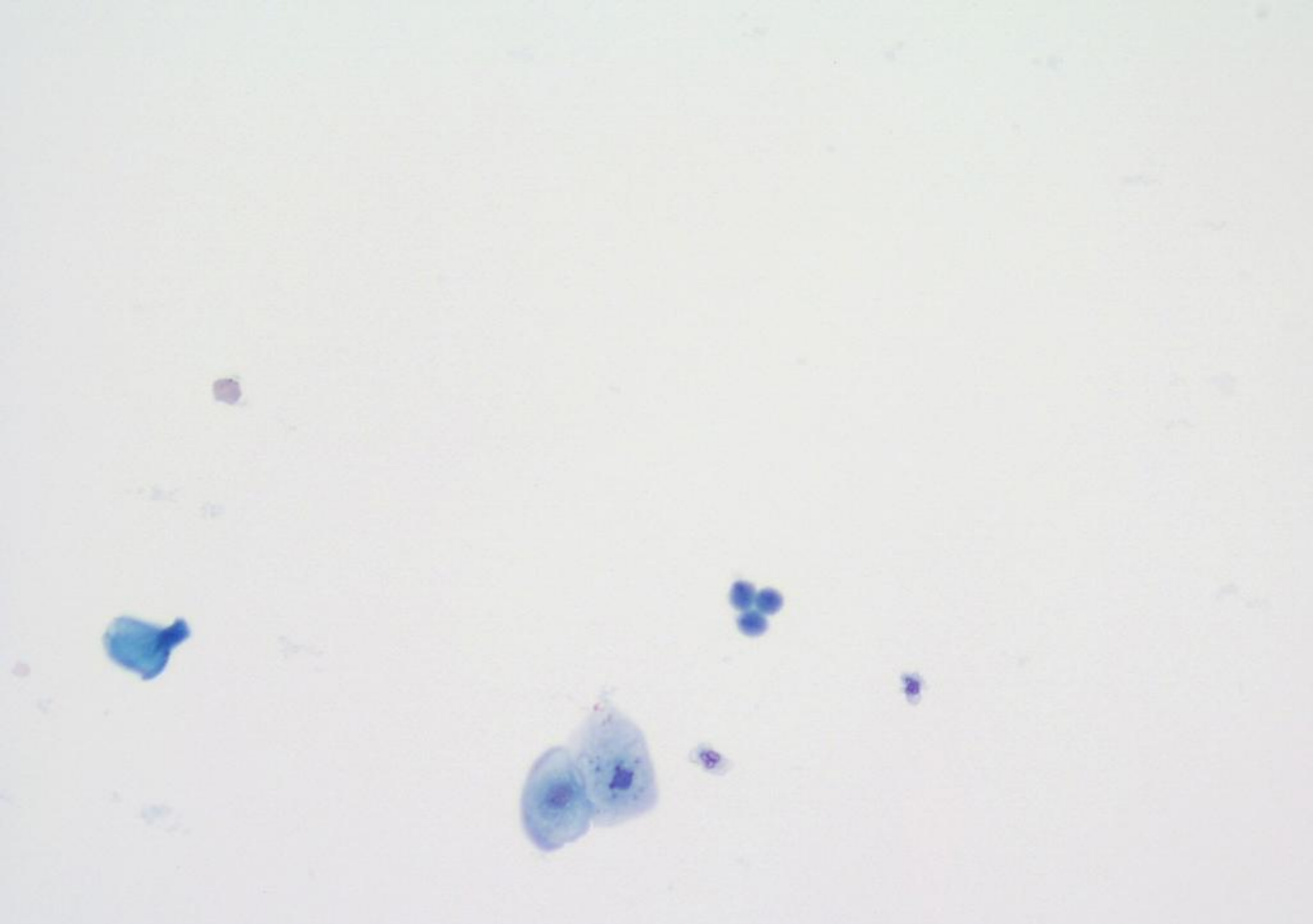
- This virus usually appears in patients with compromised immune systems or it may be transmitted from a mother to her fetus at birth
- CMV infected cells typically have a large eosinophilic or basophilic intranuclear inclusion that causes margination of the nuclear chromatin, resulting in a “bull’s eye” appearance



Trichomonas

- Trichomonads are an uncommon finding in urine and should be carefully discerned from degenerated PMN's
- In a urinary specimen, the organism is usually round and bears its diagnostic eye spot, similar to that seen in Gyn samples





Atypical Urine Cytology

- Often includes difficult or borderline cases
- Lack of consensus regarding terminology and criteria
- Urologists often regard an atypical diagnosis as “negative” when cystoscopy and imaging results are normal
- Categorizing specimens as negative or suspicious rather than atypical may provide more clinical utility to the physician/patient
- In spite of the diagnostic challenge, urine cytology continues to provide a valuable screening and monitoring function for patients with bladder tumors



Atypical Urine Cytology

Common Patterns

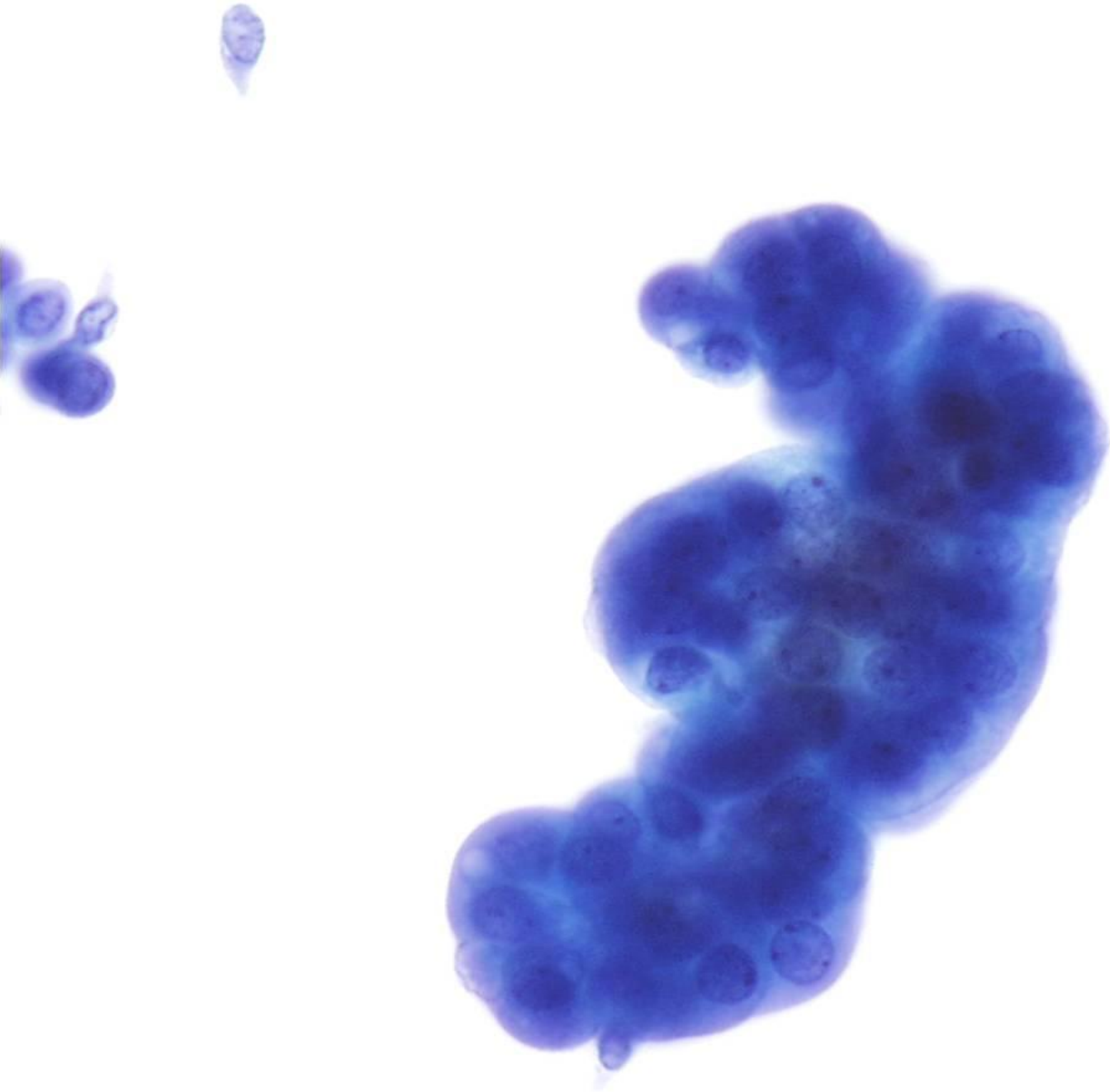
- Clusters in a voided urine
- Reactive/reparative changes
- Criteria that suggest a low grade lesion
- Rare atypical cells
- Degenerated atypical cells

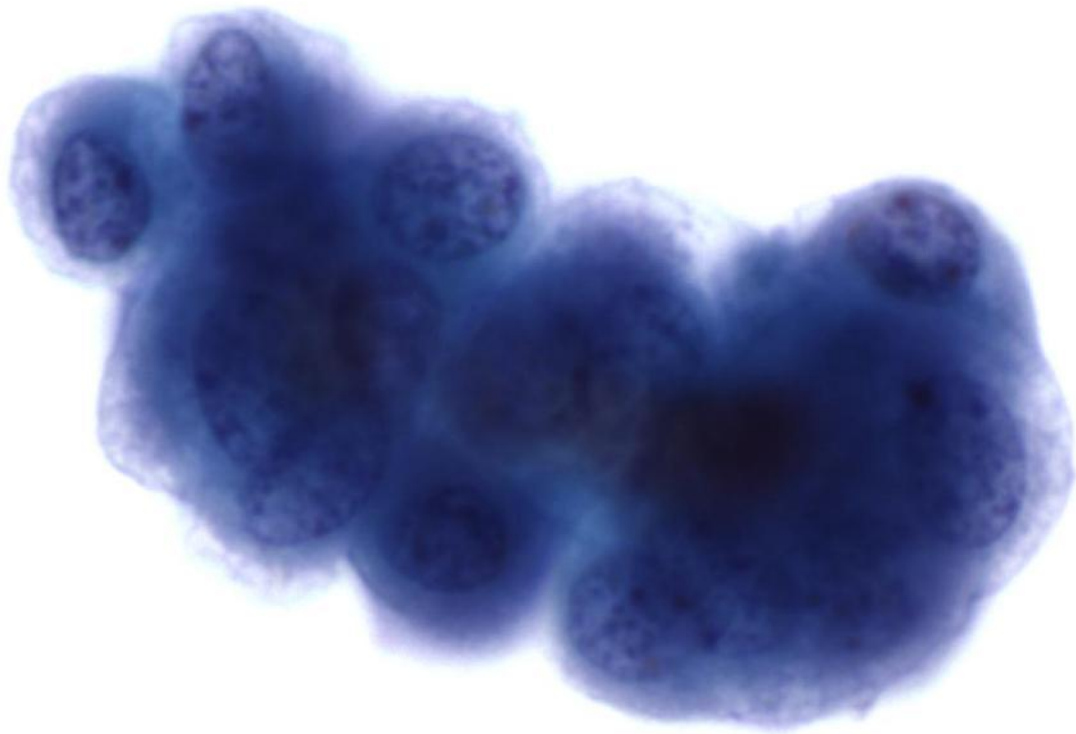


Clusters in a Voided Urine

- Not specific for diagnosing papillary tumors
 - found about 20% of the time in both benign and low grade tumor specimens
- It is important to rule out history of renal stones, recent instrumentation, cystitis, treatment effect, renal transplantation and kidney disease
- Criteria distinguishing benign tissue fragments from low grade papillary lesions are not reliable



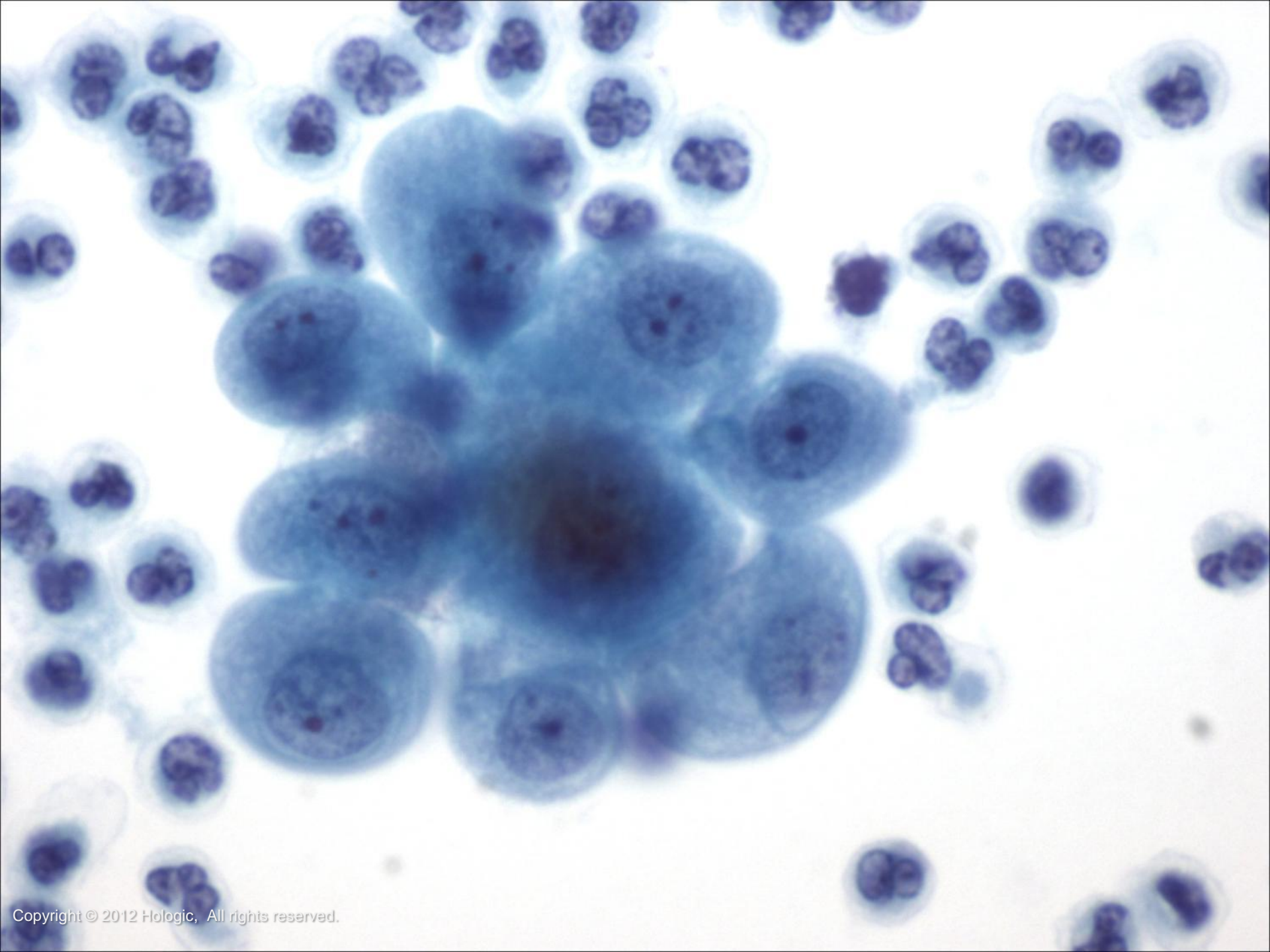




Reactive/Reparative Changes

- Criteria separating reactive atypia from neoplastic atypia are not well defined
- Cytology features favoring a reactive diagnosis:
 - Vacuolated cytoplasm
 - Prominent nucleoli
 - Intact and smooth nuclear membranes

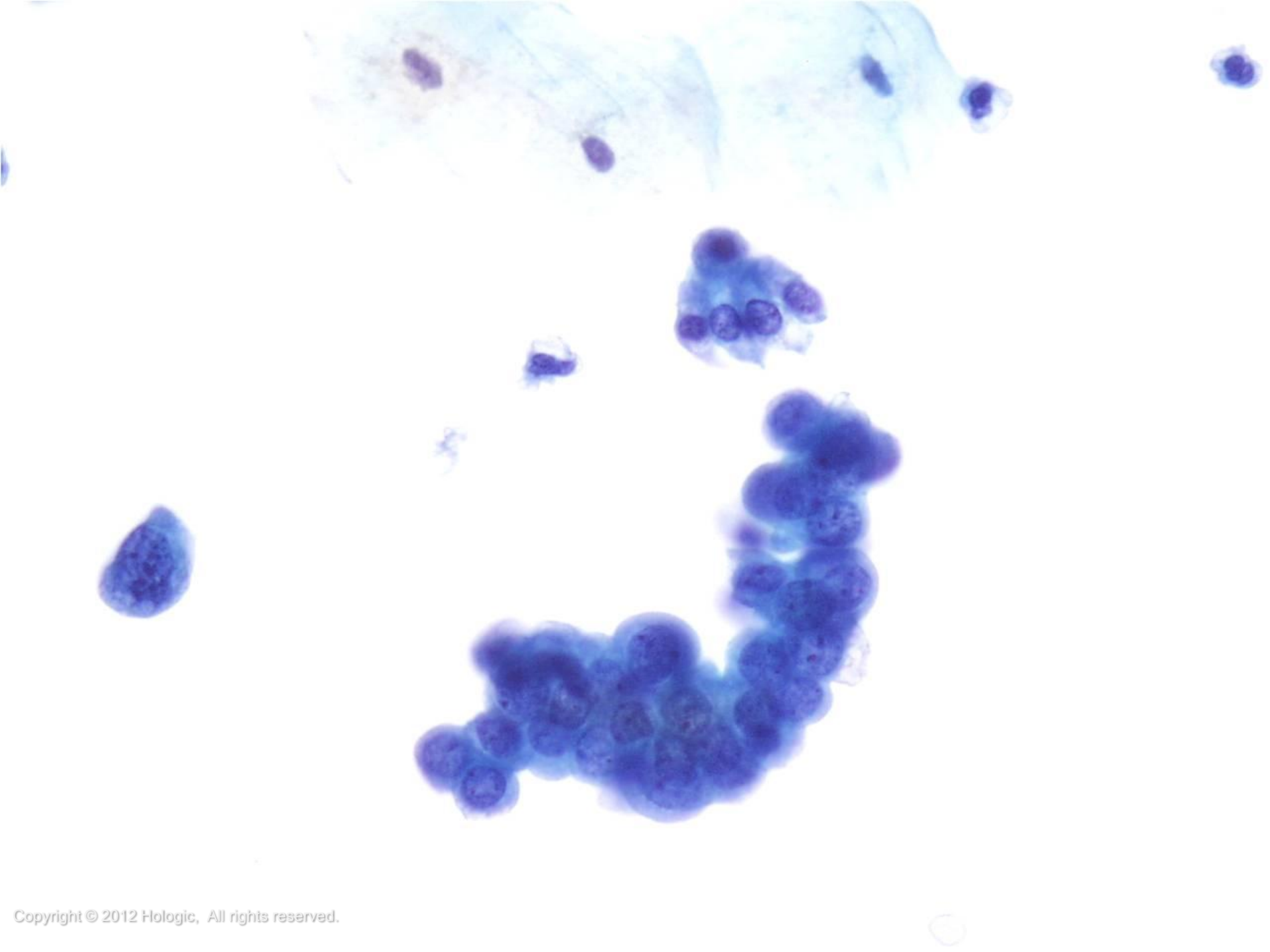




Criteria Suggestive of a Low Grade Lesion

- Criteria distinguishing benign tissue fragments from low grade papillary lesions are not reliable
- Cytology features favoring a low grade lesion:
 - N/C >50%
 - Irregular nuclear membranes
 - Cytoplasmic homogeneity
 - Papillary fragments with fibrovascular cores
 - Numerous three-dimensional cells clusters with irregular borders

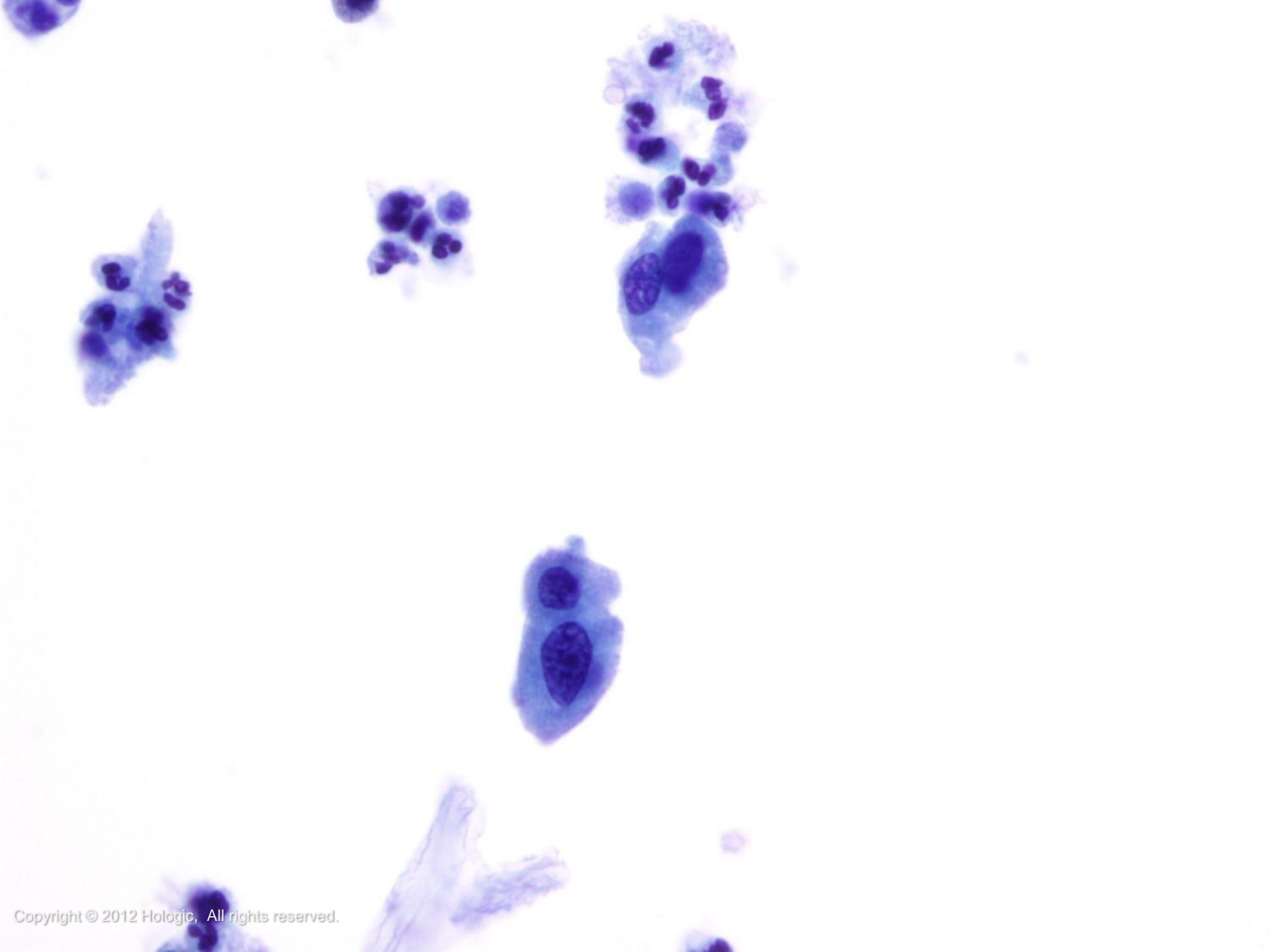


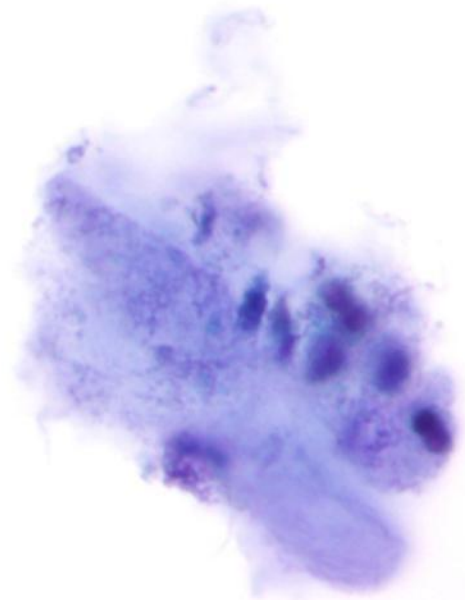
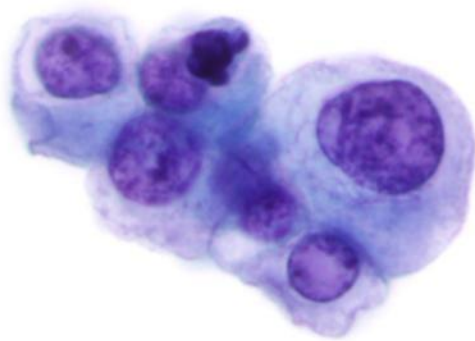


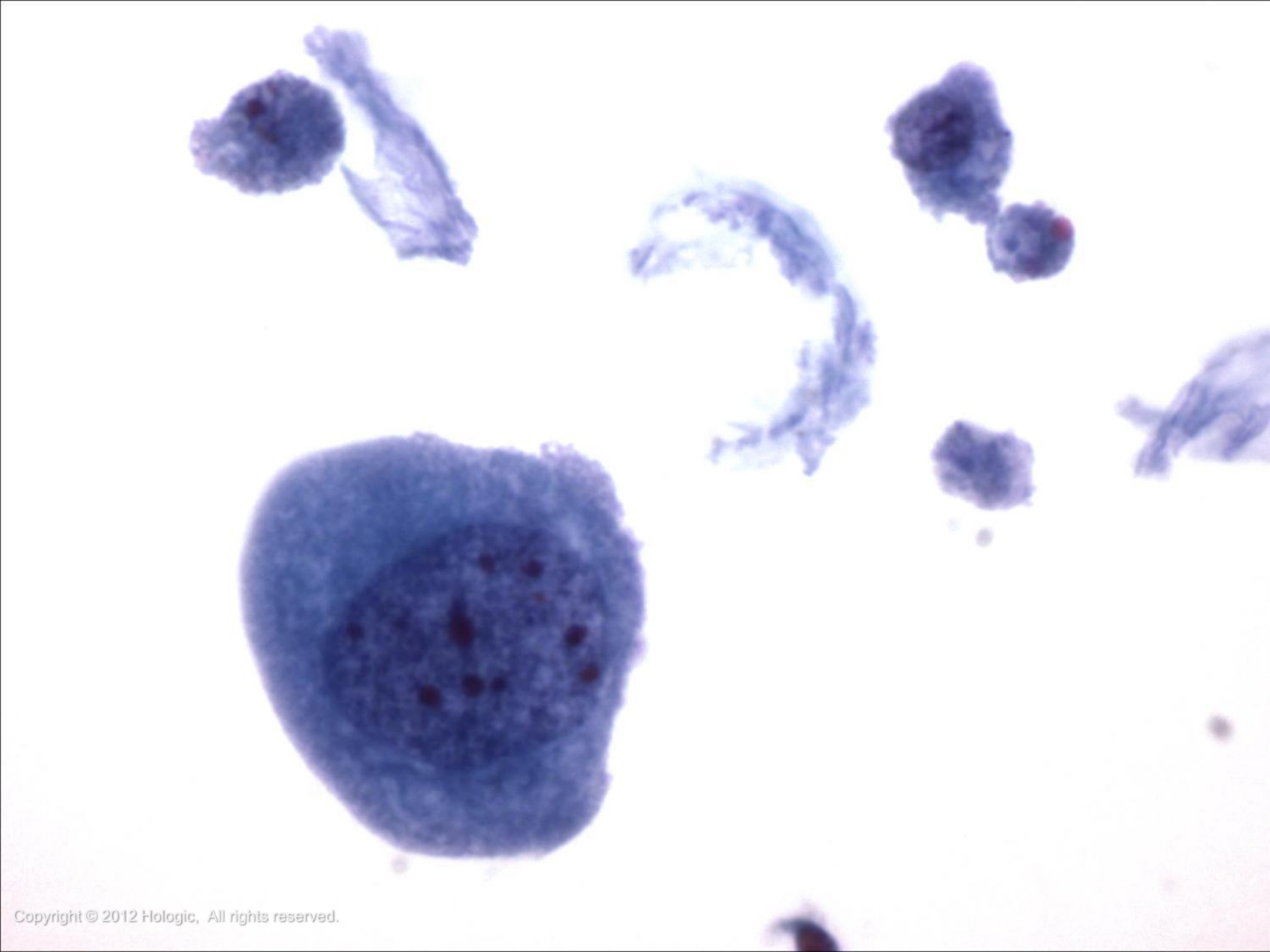
Rare Atypical Cells

- The most common cause of an atypical urine diagnosis
- Cytology features favoring benign:
 - N/C <50%
 - Minimal hyperchromasia
 - No nuclear border irregularities
- Cytology features favoring abnormal:
 - N/C >50%
 - Nuclear hyperchromasia
 - Intact, irregular nuclear membranes
 - Anisonucleosis





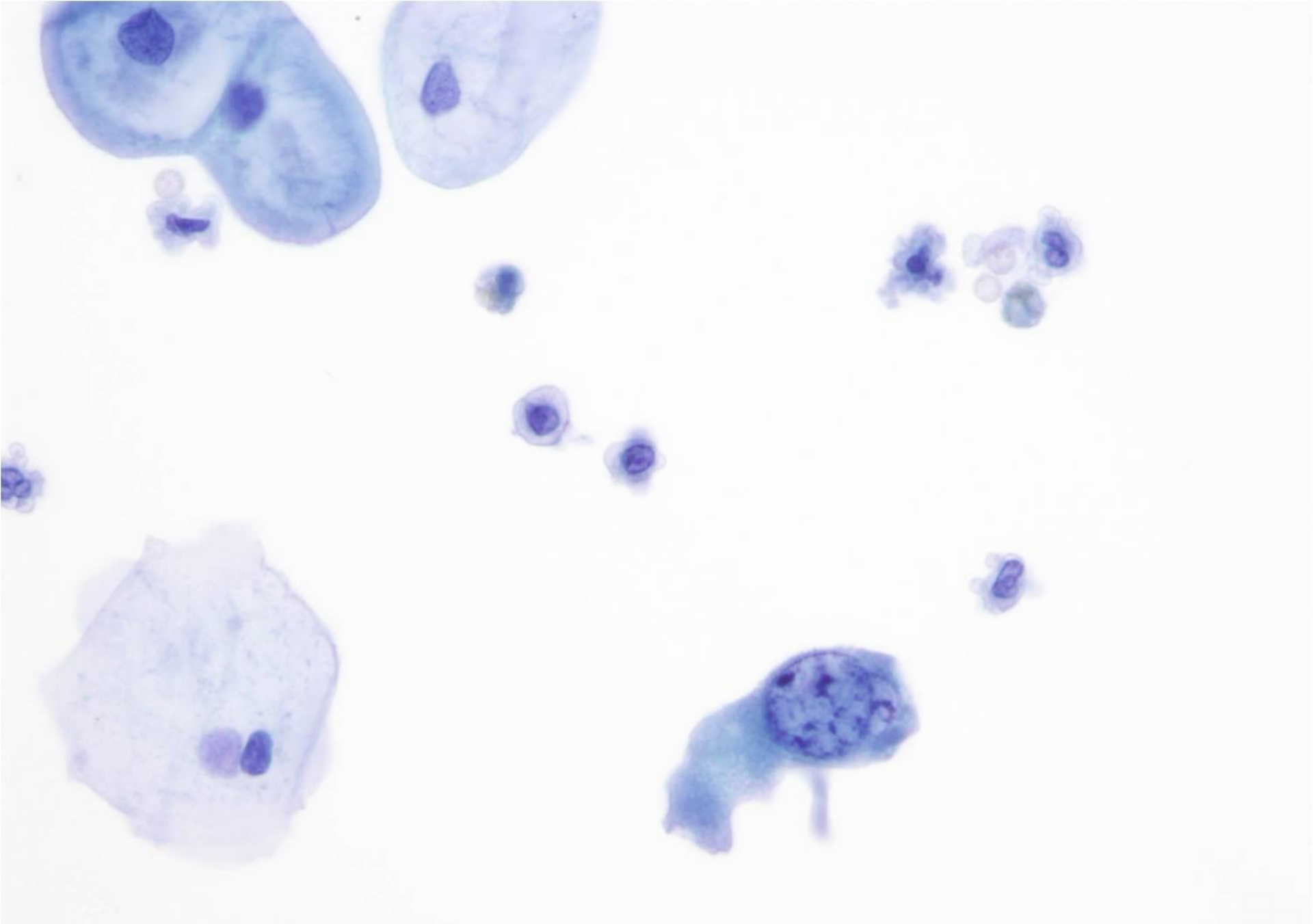




Degenerated Atypical Cells

- Commonly seen with high grade lesions and patients undergoing treatment for bladder cancer
- Overall preservation of specimen should be considered before giving an atypical diagnosis
- Cytology features favoring abnormal:
 - N/C >50%
 - Dark, smudgy chromatin
 - Intact, irregular nuclear membranes
 - Anisonucleosis





Bladder Cancer in the US Statistics

- The 5th most common cancer in men
- Effects over 50,000 people annually with an average age of 68
- Male to Female ratio of 3:1
- 10,000 deaths annually
- 5 year survival rates can range from 98% with stage 0 to 15% with stage IV
- More than 90% of bladder carcinomas are transitional cell carcinomas, 6% to 8% are squamous cell carcinomas, and 2% are adenocarcinomas
- About 75% bladder cancers are superficial



Bladder Cancer in the US

Risk Factors

- The main preventable risk factor is tobacco smoking
- High-risk population: smokers, workers in dye, rubber & leather industries, painting, aluminum, steel or any chemical industries
- Bladder cancer cells commonly show genetic aberrations of chromosomes 3, 7, 9 and 17



Bladder Cancer in the US

Treatment

- Early-stage bladder cancer is treated locally with surgical excision during cystoscopy
- Bacillus Calmette-Guerin (BCG) is a standard immunotherapy drug for high grade non-invasive bladder cancer
- Cystectomy is the removal of the bladder, used for invasive or recurrent tumors
- Advanced bladder cancer is often treated with intravesical or systemic chemotherapy



Bladder Cancer in the US

Prognosis

- Low grade bladder tumors are more likely to be cured
- High grade bladder tumors are more likely to recur and progress
- Taking all superficial bladder tumors together, about 65% will recur in the first 2 years but mainly as early non-invasive bladder cancer
- About 30% will recur as more serious disease with less chance of cure or control
- Treated patients are followed with cystoscopy at regular (typically 3 month) intervals and any new tumors visualized are removed surgically

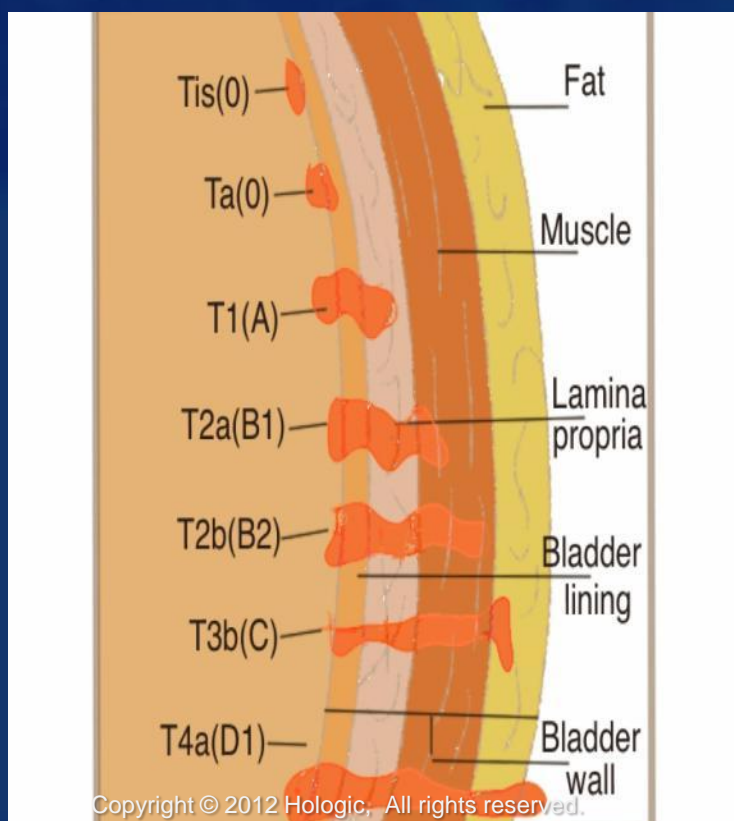


Bladder Cancer Grading

- Papilloma: papillary urothelial neoplasm of low malignant potential (PUNLMP); may recur but has a low risk of progressing
- Low grade: more likely to recur and progress compared with PUNLMP
- High grade: most likely to recur and progress compared with low grade tumors and PUNLMP



Bladder Cancer Staging



TNM Classification	Jewett-Strong Marshall	Definition
Tis	0	Limited to mucosa, flat insitu
Ta	0	Limited to mucosa, papillary
T1	A	Lamina propria invaded
T2a	B1	< halfway through muscularis
T2b	B2	> halfway through muscularis
T3	C	Perivesical fat
T4a	C	Prostate, uterus or vagina
T4b	C	Pelvic wall or abdominal wall
N1-N3	D1	Pelvic lymph node(s) involved
M1	D2	Distant metastases

Diagnosis and Monitoring

- Cystoscopy: The gold standard for diagnosis and monitoring

Post treatment

0-2 years:

2-4 years:

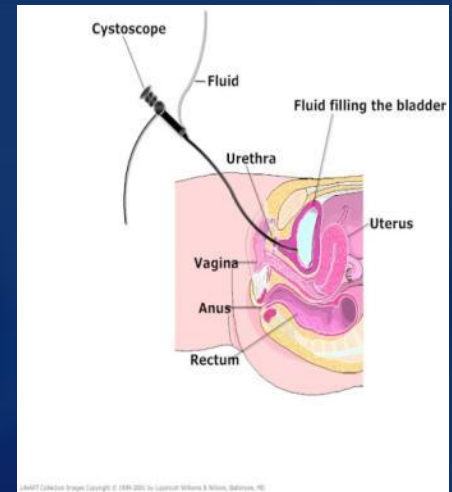
5-or more years:

Frequency

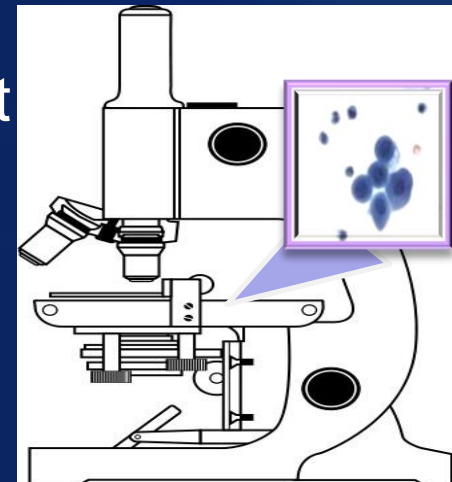
Every 3 months

Every 6 months

Yearly



- Cytology: Performed as an adjunct test to cystoscopy, often on bladder washings



Abnormal Findings

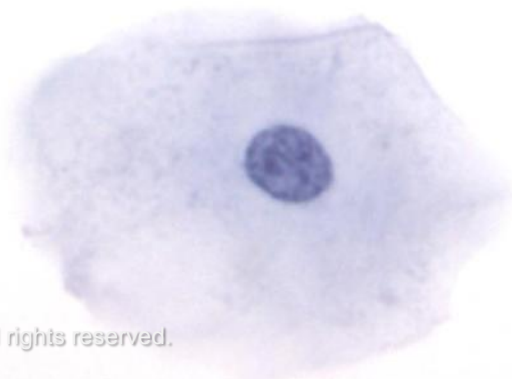
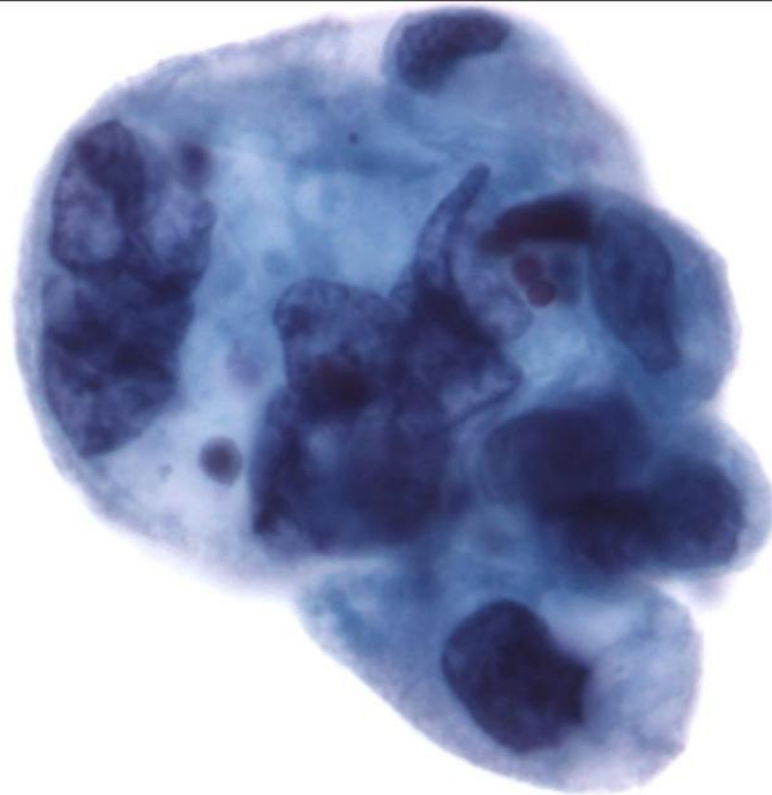
- Transitional (Urothelial) Cell Carcinoma in Situ (CIS)
- Papilloma/Papillary Urothelial Neoplasm of Low Malignant Potential (PUNLMP)
- Transitional (Urothelial) Cell Carcinoma
 - Low Grade and High Grade
- Squamous Cell Carcinoma
- Adenocarcinoma
 - Kidney
 - Prostate
- Renal Cell Carcinoma

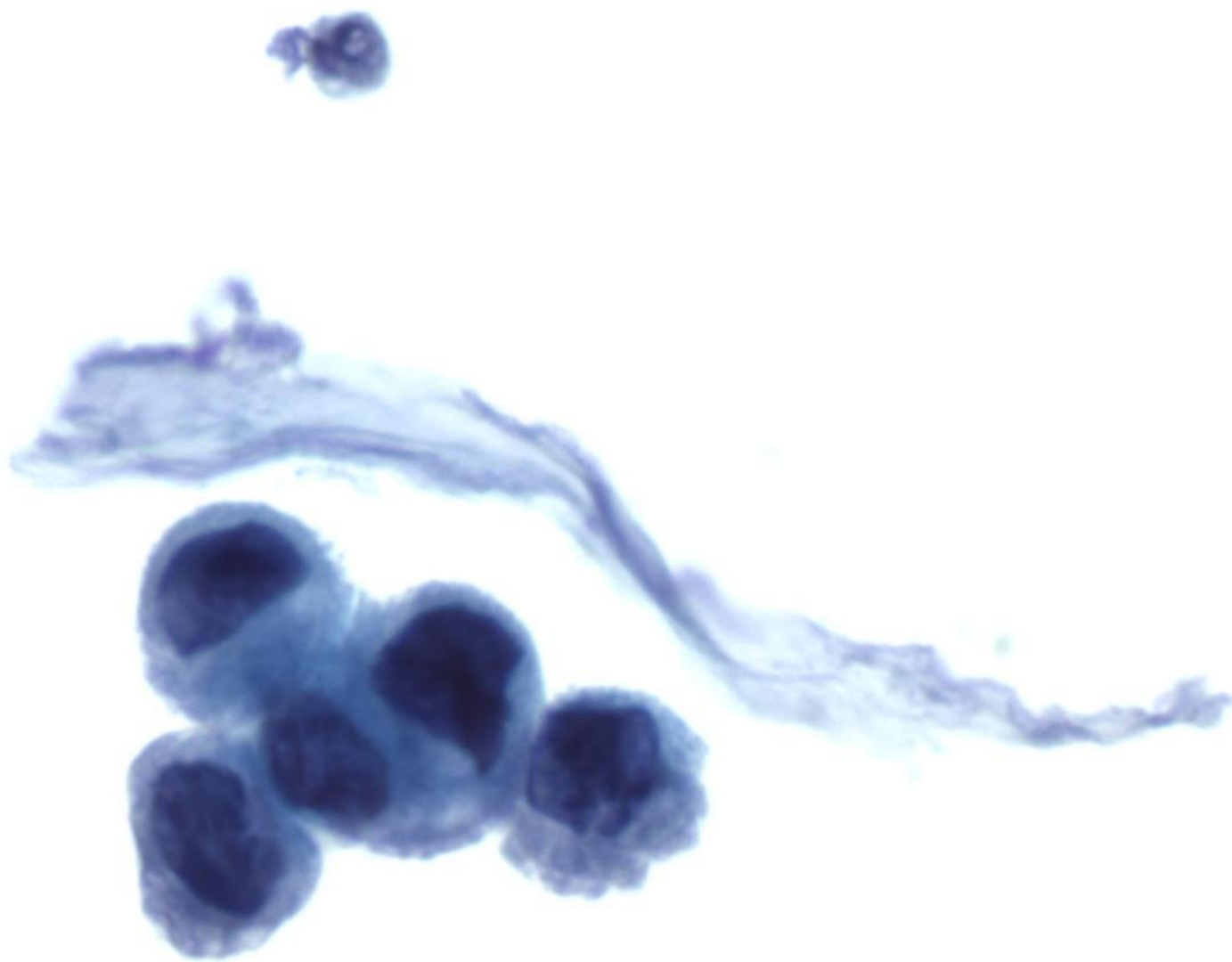


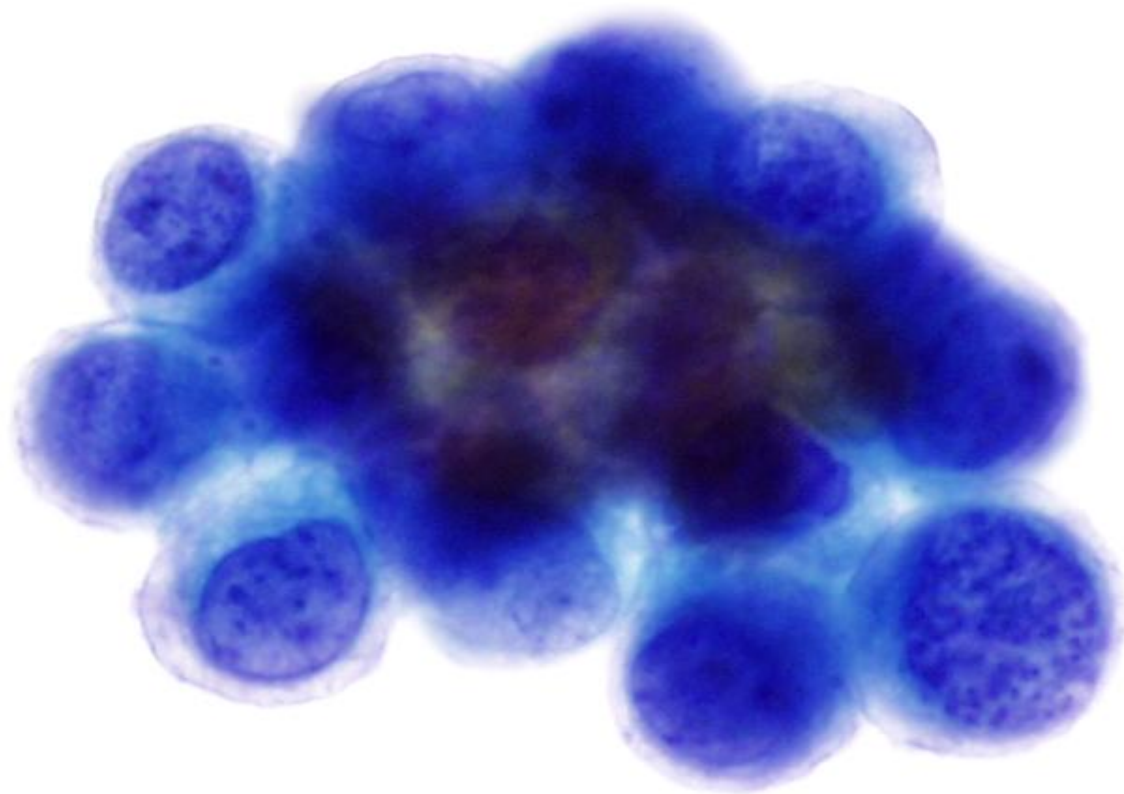
Transitional Cell Carcinoma In Situ

- Transitional Cell CIS is a flat lesion
- Cytologically, it is characterized by:
 - Abundant abnormal, enlarged urothelial cells with a high N/C ratio
 - Hyperchromatic, coarsely granular nuclei often showing mitotic activity
 - Abnormal cells dispersed both singly and in small non-polar sheets
 - Clean background









Papilloma

- Ongoing controversy regarding classification of these lesions as true papillomas or PUNLMPs
- Histologically seen as a papillary lesion with little to no cytologic atypia
- Best defined as rare lesions that occur primarily in young patients with low recurrence
- Difficult to recognize on cytology



Papillary Urothelial Neoplasm of Low Malignant Potential (PUNLMP)

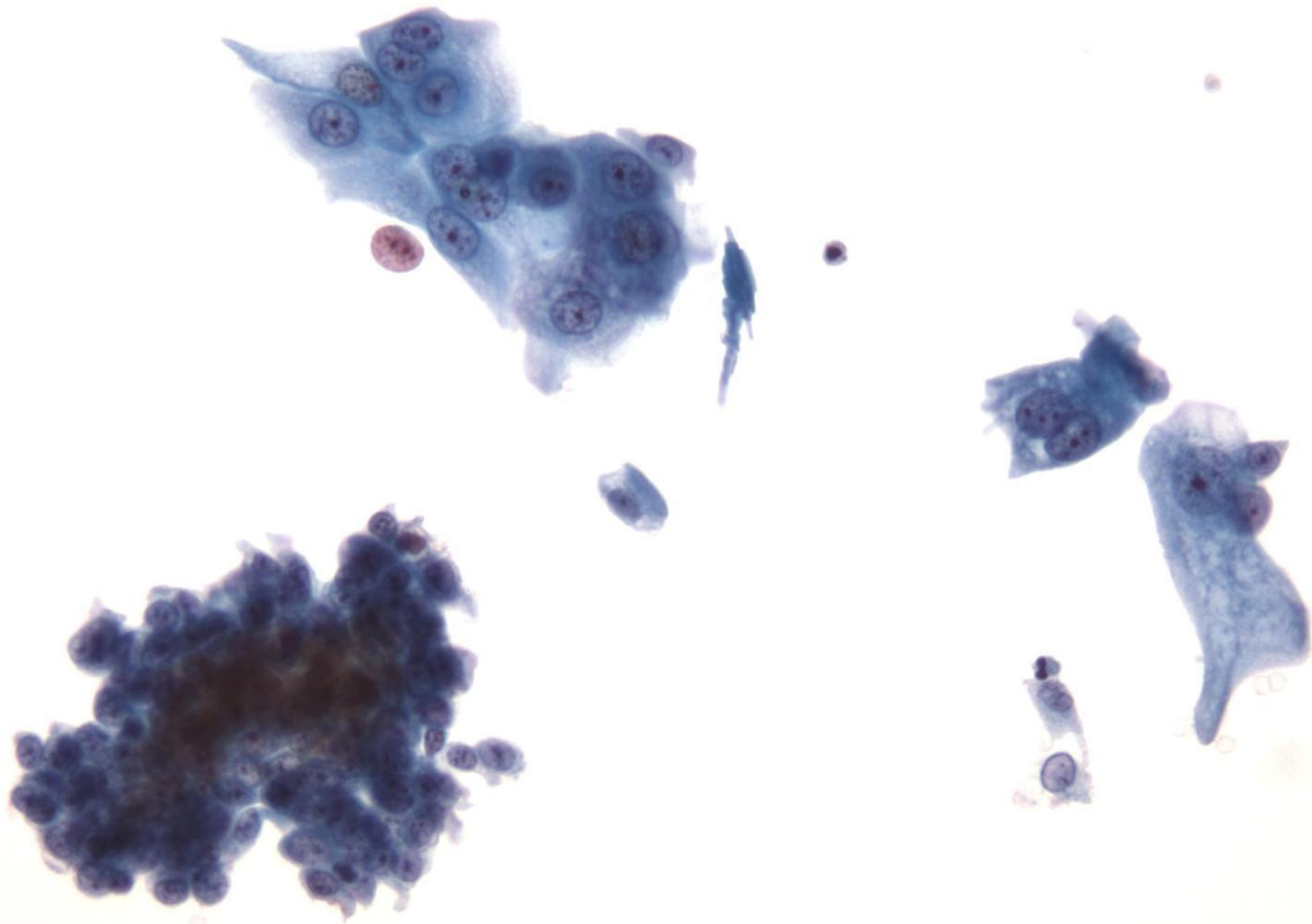
- **PUNLMP features:** *NOTE-There are no “reliable” cytologic criteria for diagnosing these tumors*
 - Increased number of bland urothelial cells in loose clusters and papillary groups with irregular edges
 - The papillary groups must be distinguished from those present due to instrumentation, stone induced artifact or low grade urothelial cancer

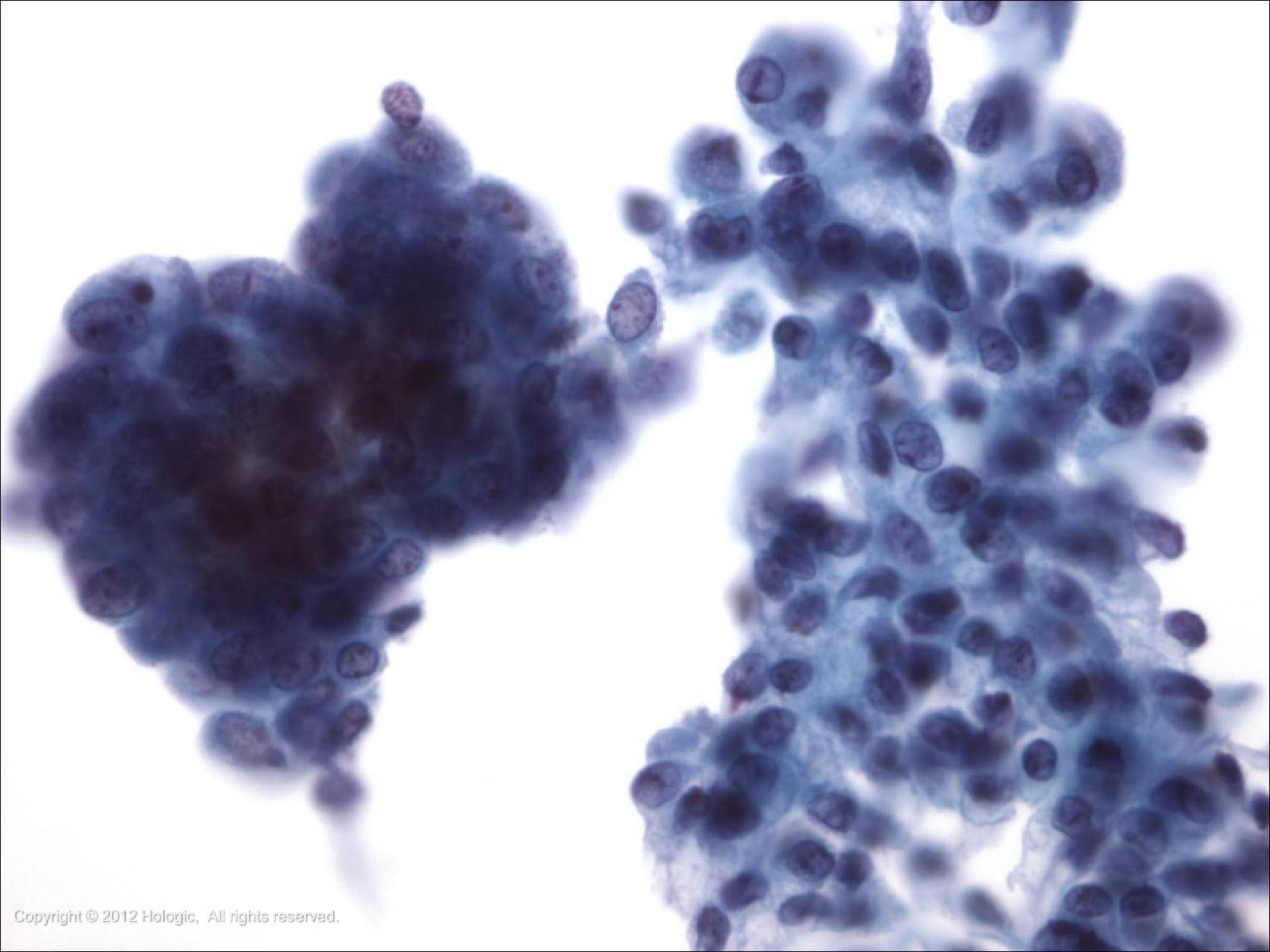


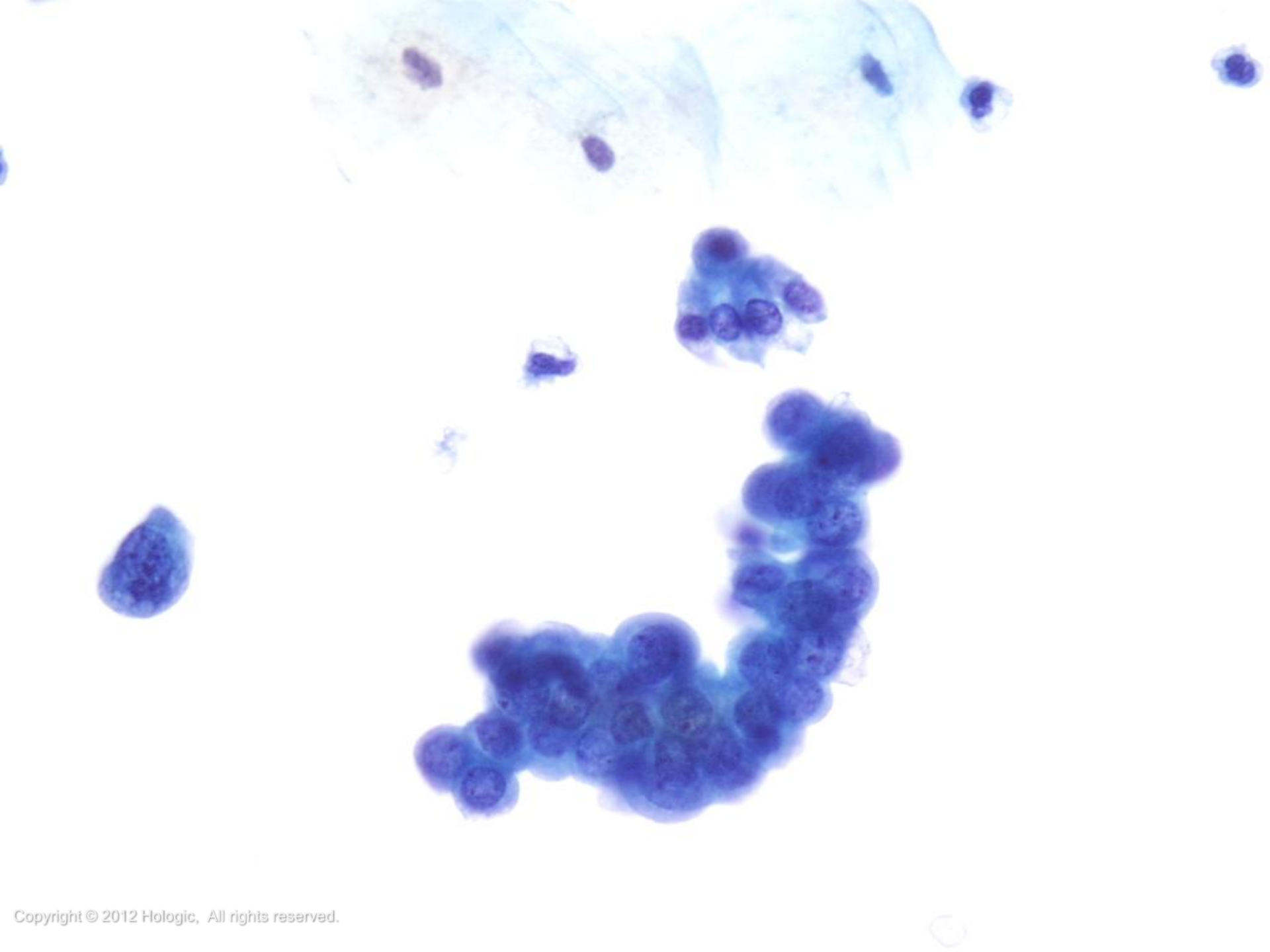
Low Grade Transitional Cell Carcinoma

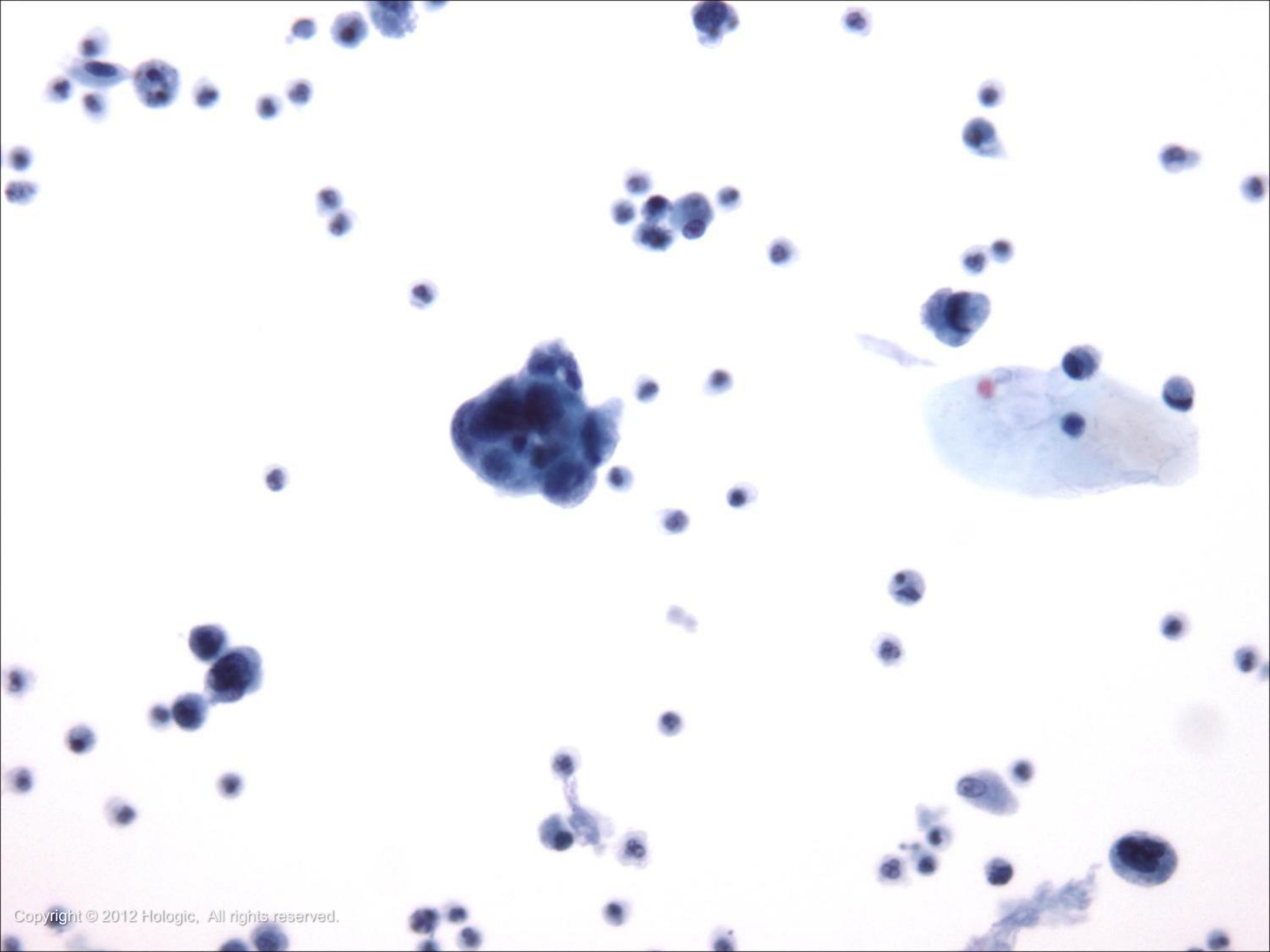
- Low Grade TCC features:
 - Increased cellularity including an increased number of urothelial clusters which may be papillary
 - Irregular nuclear membranes
 - Granular and evenly distributed chromatin
 - High N/C ratios with the nuclei bulging out of the cytoplasm
 - Nucleoli are indistinct or absent







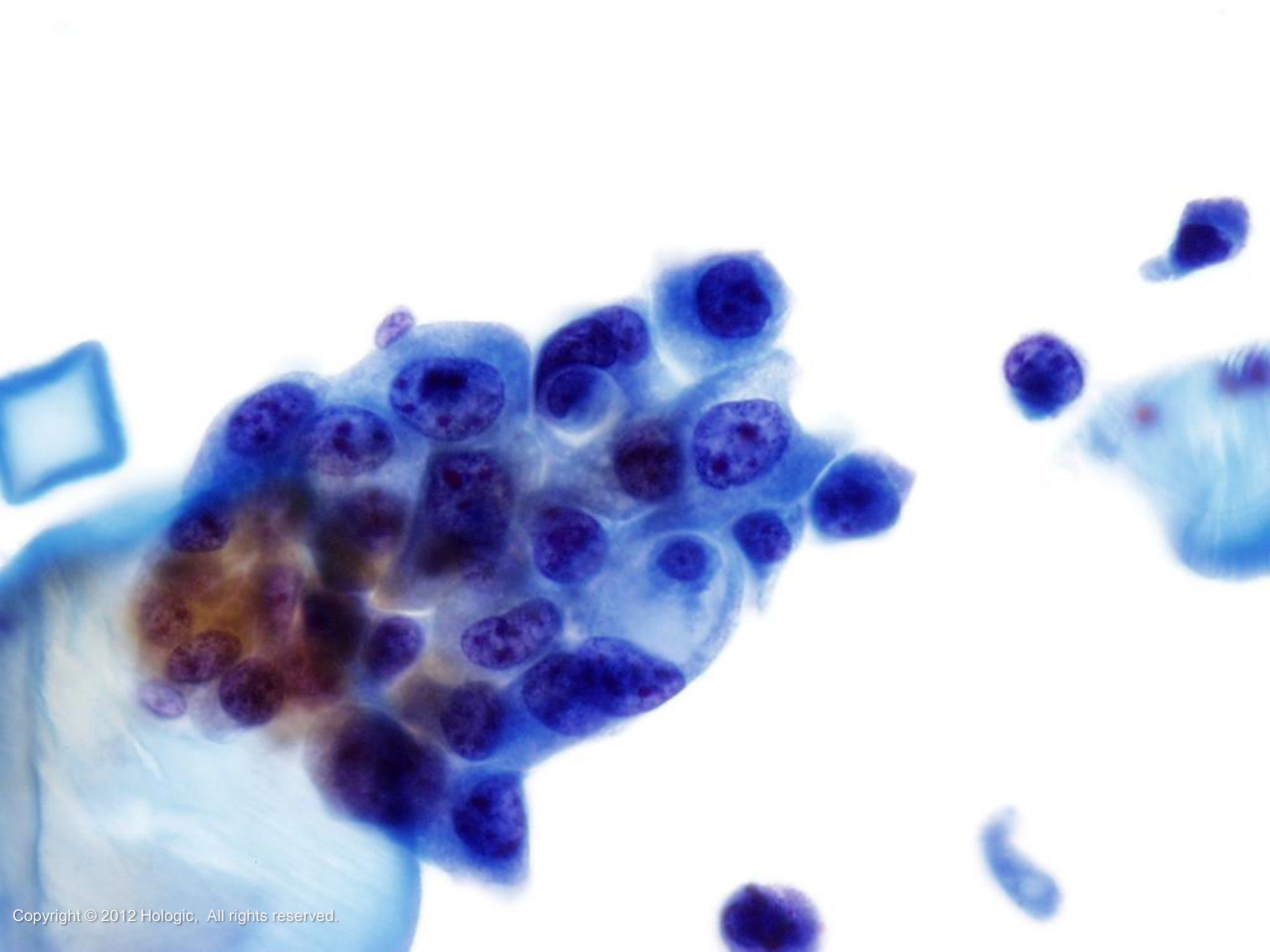


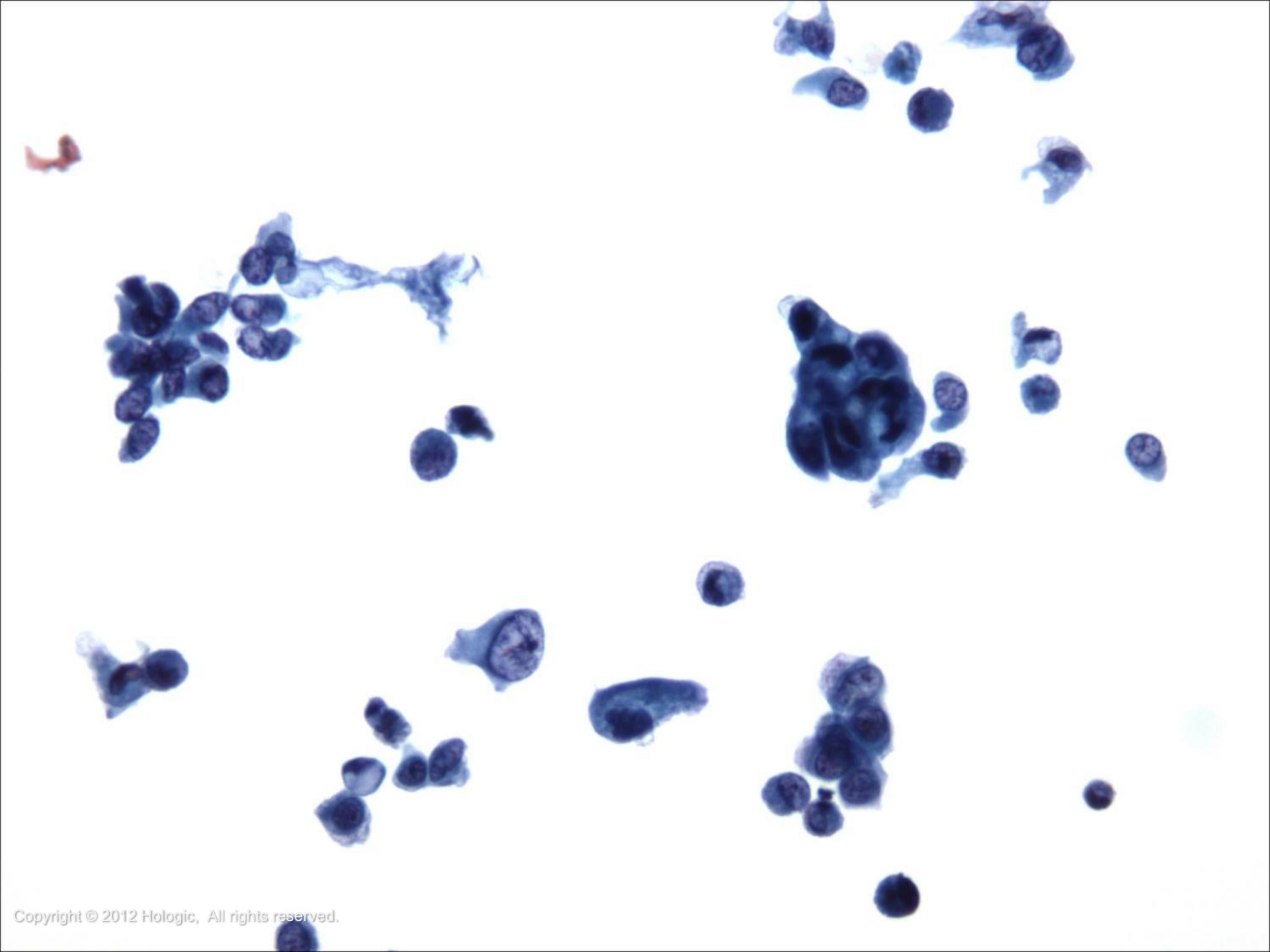


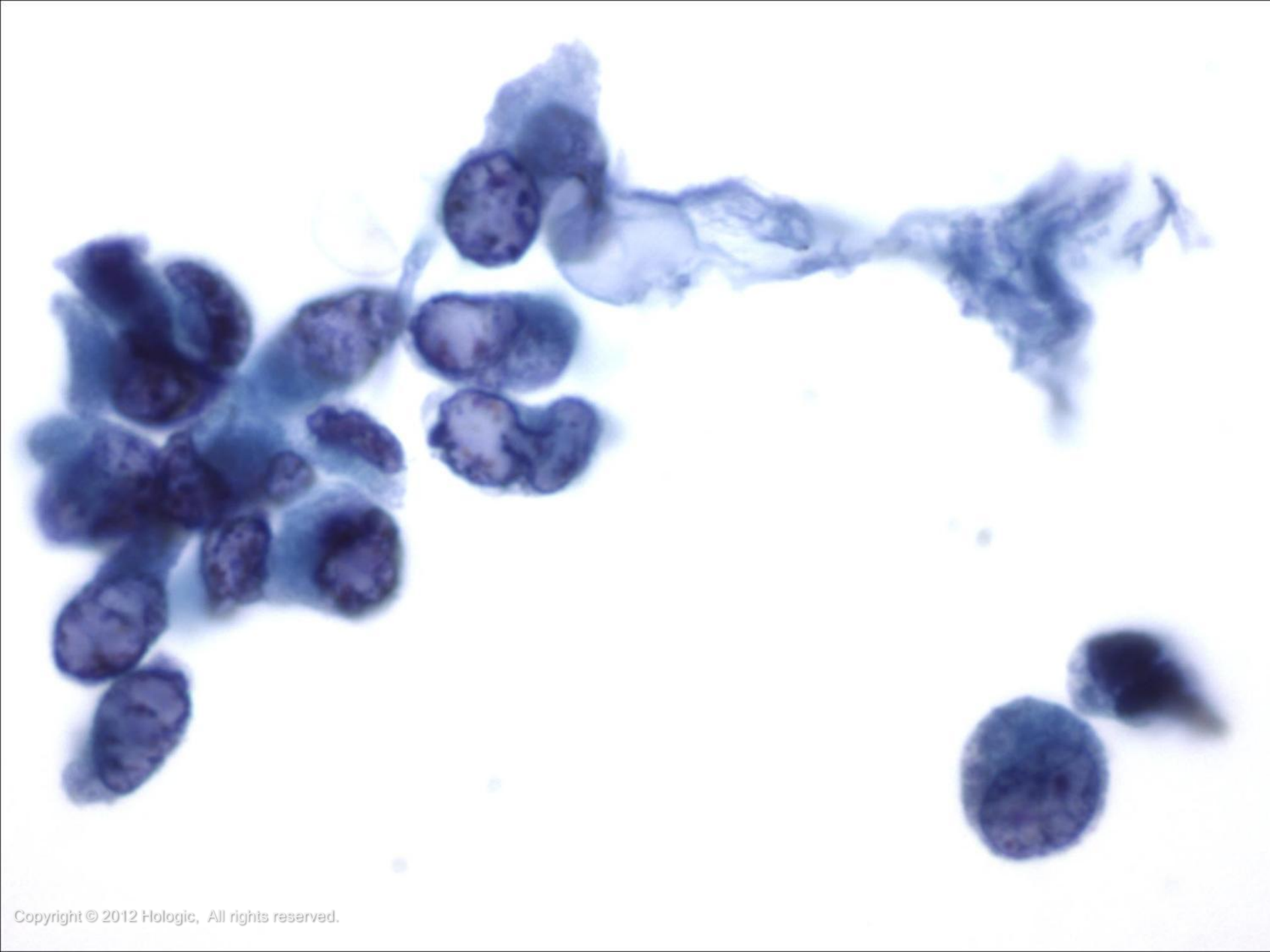
High Grade Transitional Cell Carcinoma

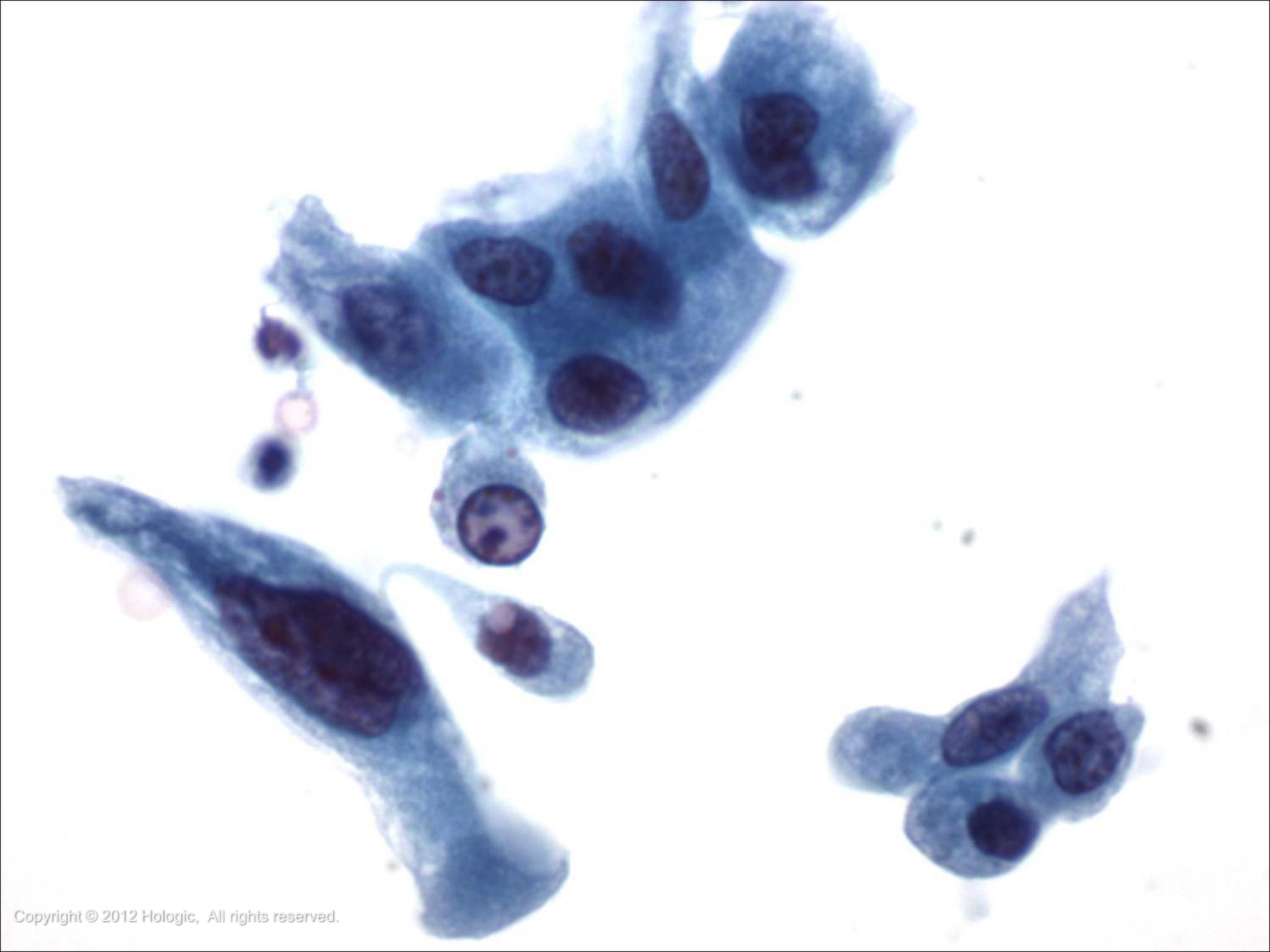
- High Grade TCC features:
 - Single, bizarre cells whose features include irregular nuclear borders, high N/C ratios, marked pleomorphism, parachromatin clearing, thickened nuclear borders, large irregular nucleoli and occasional mitoses
 - Background may contain blood, debris and inflammatory cells
 - May have squamous or glandular differentiation in more poorly differentiated tumors

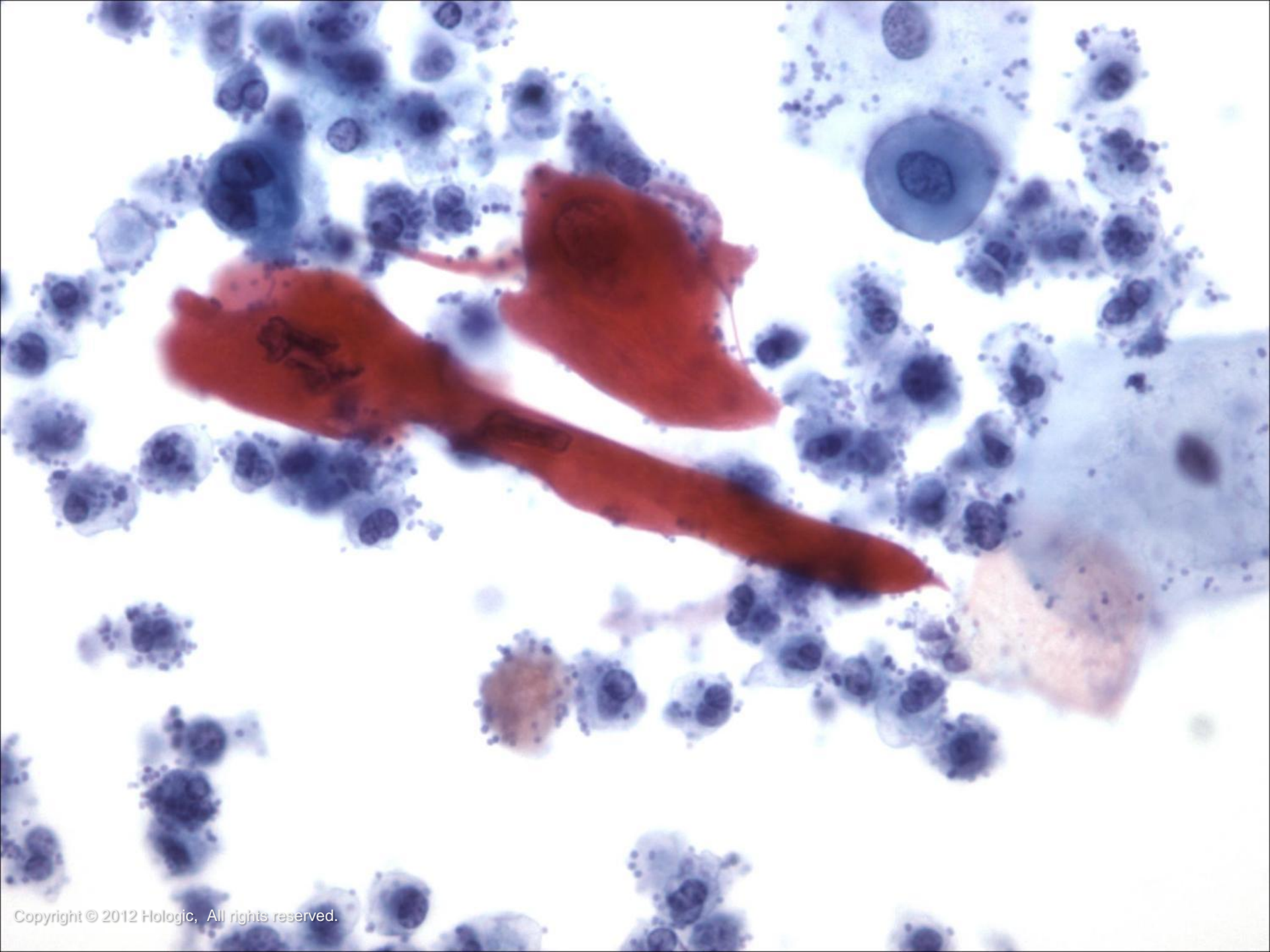








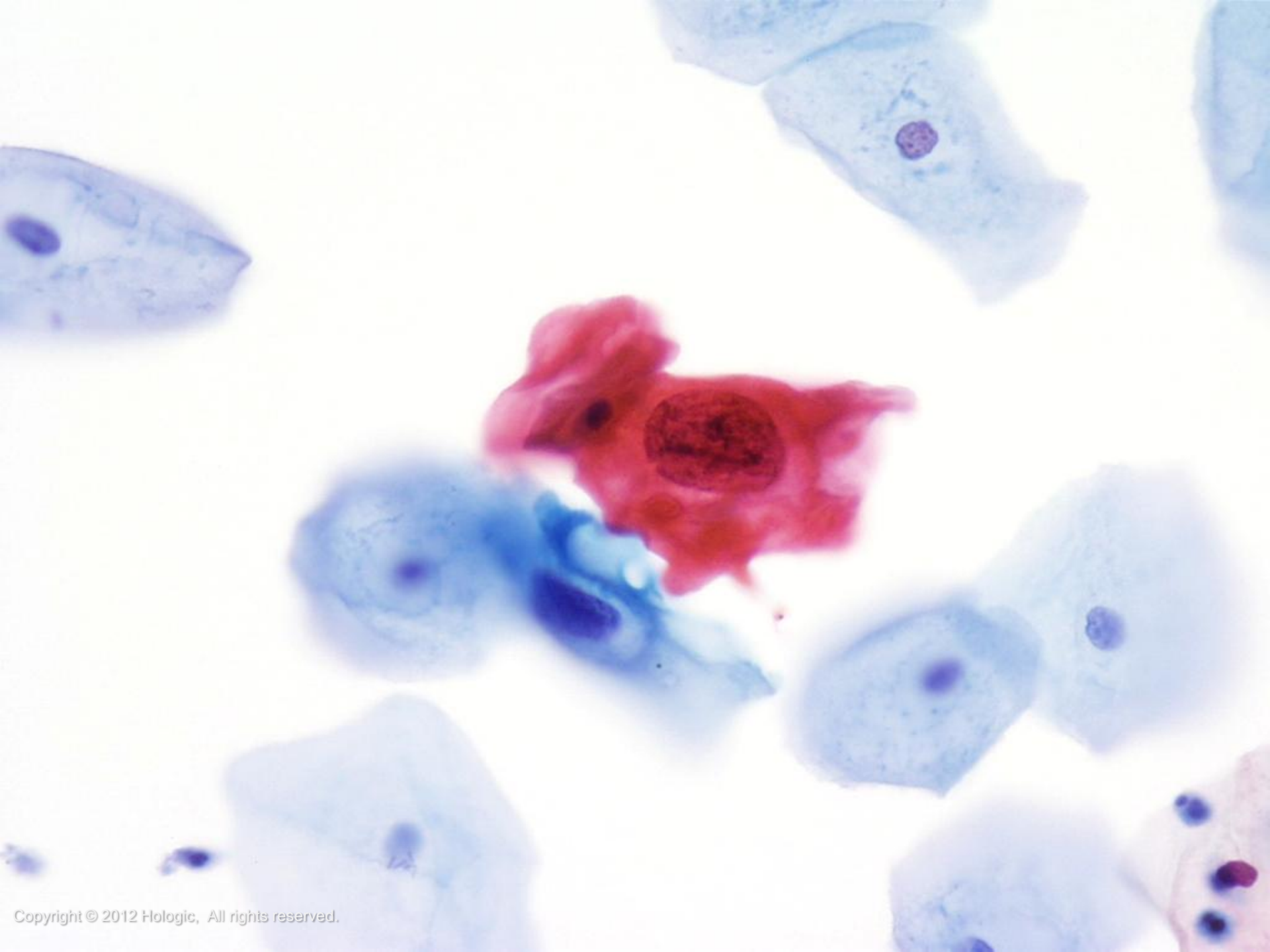




Squamous Cell Carcinoma

- Characteristics:
 - May arise
 - Within squamous metaplasia
 - In the urethra
 - As a result of chronic *Schistosomas* infection
- Often has keratinizing and other classically recognizable features
- To distinguish from a TCC with squamoid differentiation, look for abnormal urothelial cells





Adenocarcinoma

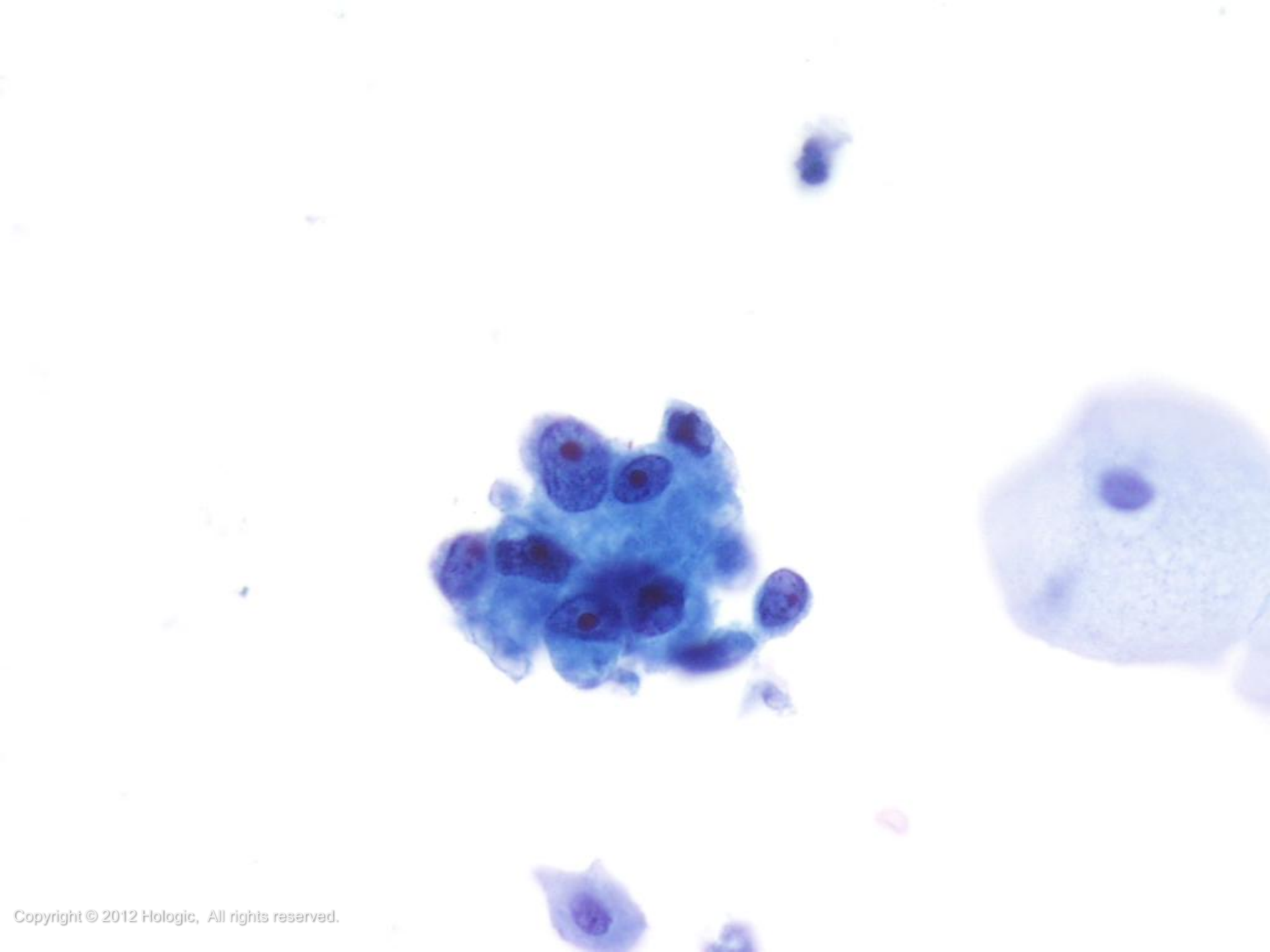
- Bladder:
 - Very rare – 2% of bladder tumors
 - Features include three-dimensional clusters of round, vacuolated cells with irregular nuclei and prominent nucleoli



Adenocarcinoma

- Kidney:
 - Only sheds into urine in end stage disease
 - Typically, cells are round with vacuolated cytoplasm
 - Nuclei are round with prominent nucleoli
 - Appearance may vary according to differentiation of tumor

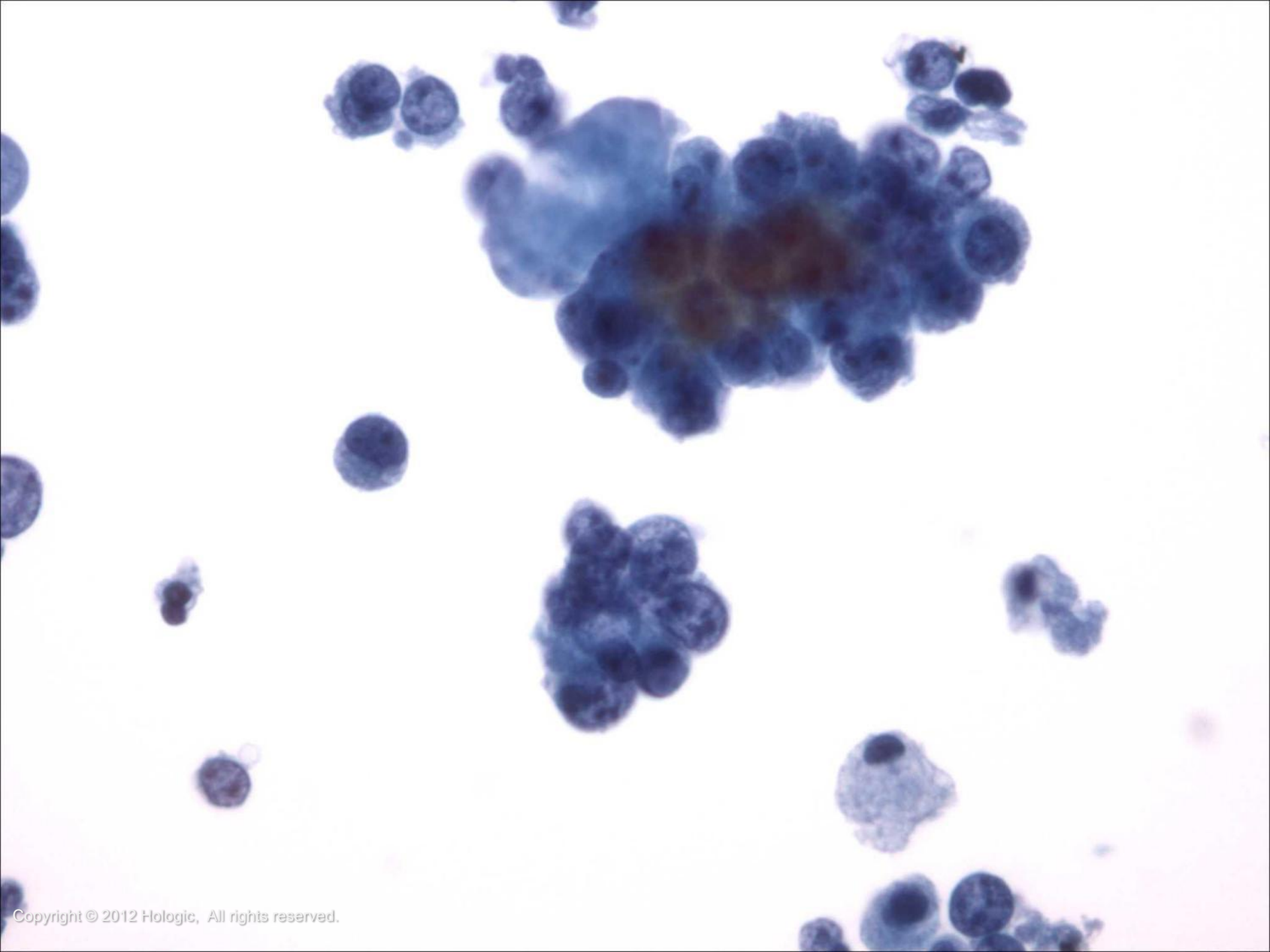


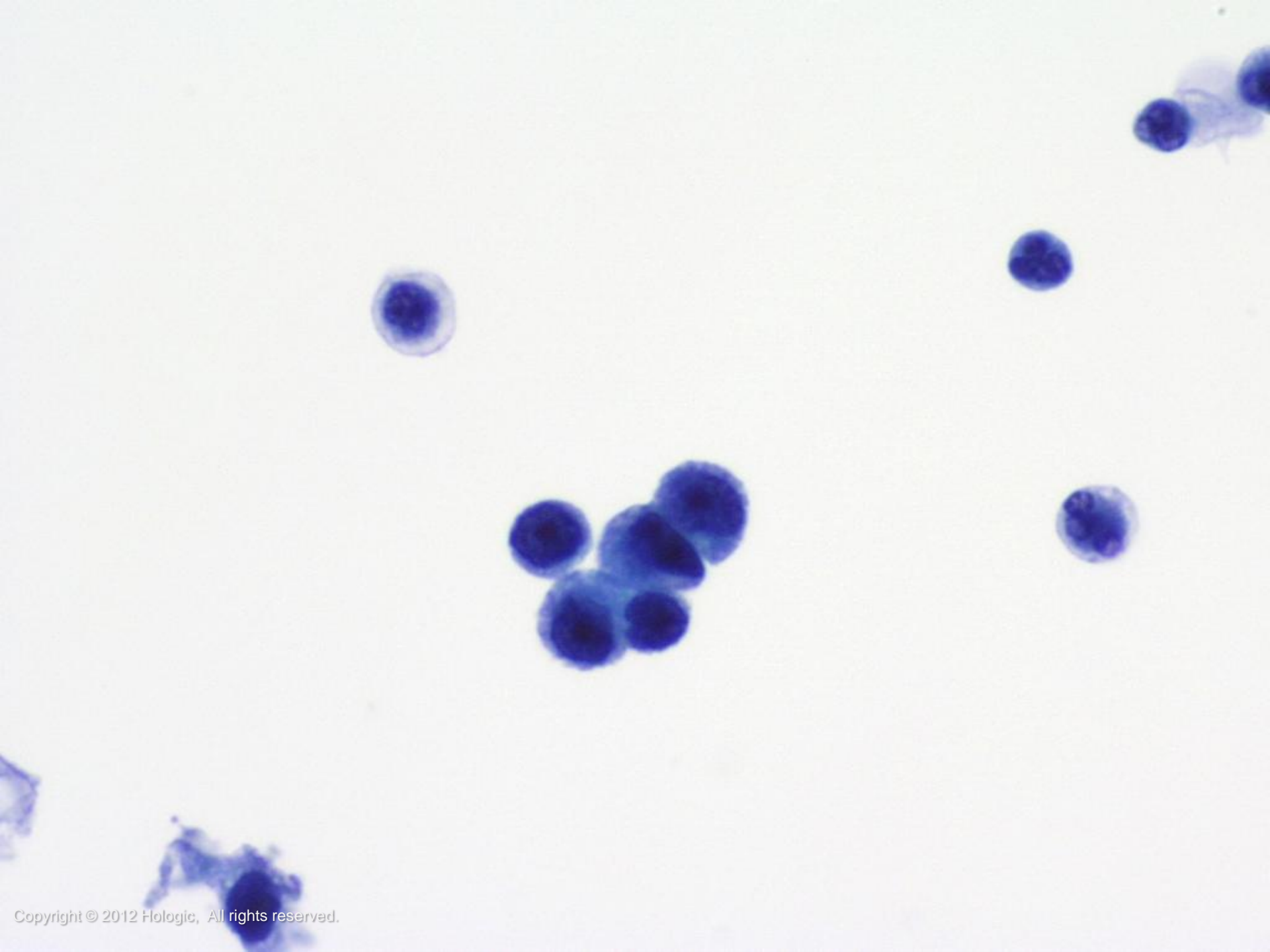


Adenocarcinoma

- Prostate:
 - May shed after instrumentation (especially of prostate) or when disease has invaded bladder
 - Typically is characterized by loose clusters of glandular cells with prominent nucleoli







Ancillary Testing

Fluorescence In Situ Hybridization (FISH)
for the Detection and Monitoring of
Urothelial Carcinoma



Fluorescence In Situ Hybridization (FISH)

- Technique used to map the presence or absence of targeted genomic sequences in chromosomes using fluorescent probes
- The targeted genes within the chromosomes are then detected using a fluorescent microscope

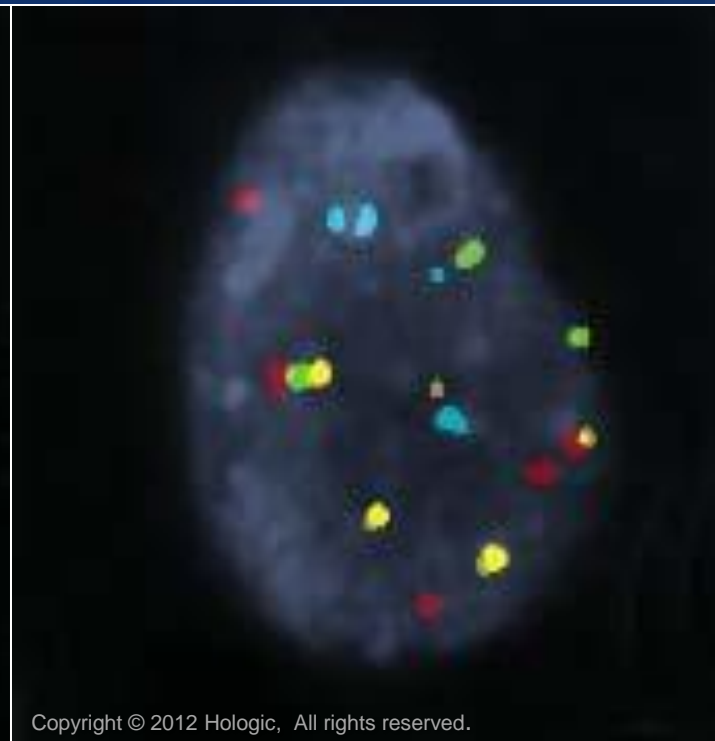
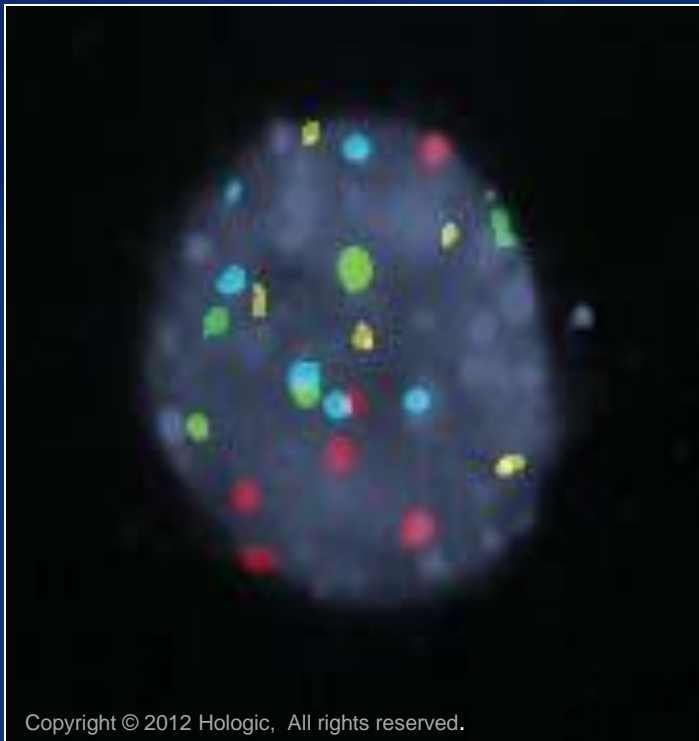


UroVysion™ Bladder Cancer FISH Assay

- Additional testing method for the initial detection of bladder cancer in patients with hematuria suspected of having bladder cancer and monitoring for recurrence
- Detects aneuploidy in chromosomes 3, 7, 17 and the loss of 9p21 locus using Fluorescence In Situ Hybridization



Urine processed by UroCyte[®] method



Trademark Statement

CytoLyt, Hologic, PreservCyt, ThinPrep, and UroCyte are registered trademarks of Hologic, Inc. and/or its subsidiaries in the United States. CytoLyt, Hologic, PreservCyt, ThinPrep, UroCyte and associated logos are trademarks of Hologic, Inc. and/or its subsidiaries in other countries.

UROVYSION is a trademark of the Abbott Group of companies



All other trademarks are the property of their respective owners.

For more information...

- Visit our websites: www.hologic.com,
www.thinprep.com, www.cytologystuff.com
 - Product Catalog
 - Contact Information
 - Complete Gynecologic and
Non-gynecologic Bibliographies
 - Cytology Case Presentation and
Unknowns
 - Slide Library Request Form



Bibliography

Astarita, Robert W: *Practical Cytopathology* 1990: 303-335.

Bibbo, Marluce: *Comprehensive Cytopathology* 1991: 433-466.

Cibas, E., Ducatman, B.: *Cytology: Diagnostic Principles and Clinical Correlates 3rd edition* 2009: 105-127.

DeMay, Richard M: *The Art & Science of Cytopathology* 1996: 386-409.

Koss, Leopold G: *Diagnostic Cytology and its Histologic Bases*, 4th edition: 1991: 890-1000.

McKee, Grace T: *Cytopathology* 1997: 217-231.

Renshaw, AA: Subclassifying atypical urinary cytology specimens. *Cancer Cytopathology* 2000;90:222-229.



Bibliography

ThinPrep® 2000 Operator's Manual

ThinPrep 5000 Operator's Manual

www.texashte.com/documents/curriculum/a_p/urinary_system.pdf

www.WebMD.com

www.fccc.edu

www.cancer.net

www.cancer.org

www.tree.com



Bibliography

Images:

Bich, Brian. *Ureter, Bladder*. 2008. *Photograph*. Lake Superior College, Duluth, MN. Web. *Lake Superior College*.

[<http://employee.lsc.edu/faculty/BrianBich/Picture%20Library/FormAllItems.aspx?RootFolder=%2Ffaculty%2FBrianBich%2FPicture%20Library%2FAnat%2DPhys%20II%20%28Biol%201141%29&View={997D7559-348B-48F0-A9FE-07741C9C8B65}>]

SmartDraw® (Standard Edition) [Software]. (2011). Retrieved from <http://www.smartdraw.com>

ThinPrep® Non-Gyn Morphology Reference Atlas: Urinary: 119-147.



<http://www.wpclipart.com>